EISSN - 3062-0856

Sports Traumatology & Arthroscopy

STArt



Volume 1
Issue 1
Year 2024

KARE PUBLISHING

STArt
TUSYAD
Sports Traumatology & Arthroscopy

Editorial Board

Editor

Ozkan Kose, MD, PhD, Prof.
University of Health Sciences, Antalya Training and Research Hospital, Department of Orthopedics and Traumatology, Antalya, Türkiye

Associate Editors

Ahmet Firat, MD, Prof.
VM Medicalpark Ankara Hospital, Department of Orthopaedics and Traumatology, Ankara, Türkiye
Baris Yilmaz, MD, Assoc. Prof.
University of Health Sciences, Fatih Sultan Mehmet Training and Research Hospital, Department of Orthopedics and Traumatology, Istanbul, Türkiye

Technical Editors

Ahmet Emre Paksoy, MD, Assoc. Prof.
Ataturk University, Medical Faculty, Department of Orthopedics and Traumatology, Erzurum, Türkiye
Aliekber Yapar, MD, Assoc. Prof.
University of Health Sciences, Antalya Training and Research Hospital, Department of Orthopedics and Traumatology, Antalya, Türkiye
Halis Atil Atilla, MD, Assoc. Prof.
University of Health Sciences, Ankara City Hospital, Department of Orthopedics and Traumatology, Ankara, Türkiye
Kerim Oner, MD, Assoc. Prof.
Karadeniz Technical University, Medical Faculty, Department of Orthopedics and Traumatology, Trabzon, Türkiye
Mustafa Tekin, MD, Assoc. Prof.
Cukurova University, Medical Faculty, Department of Orthopedics and Traumatology, Adana, Türkiye
Taha Kizilkurt, MD, Assist. Prof.
Istanbul University, Medical Faculty, Department of Orthopedics and Traumatology, Istanbul, Türkiye

Editorial Board

Ahmet Aslan, MD, Prof.
Alanya Alaaddin Keykubat University, Medical Faculty, Department of Orthopaedics and Traumatology, Alanya, Türkiye
Ahmet Yildirim, MD, Assoc. Prof.
University of Health Sciences, Konya City Hospital, Department of Orthopedics and Traumatology, Konya, Türkiye
Alper Kaya, MD, Prof.
Department of Orthopedics and Traumatology, Faculty of Medicine, Acibadem Mehmet Ali Aydinlar University, Istanbul, Türkiye
Atacan Atalar, MD, Prof.
Acıbadem Mehmet Ali Aydınlar University, Medical Faculty, Department of Orthopedics and Traumatology, Istanbul, Türkiye
Baran Sarikaya, MD
Orthopaedics and Traumatology, Ankara Bilkent City Hospital, Ankara, Türkiye
Baris Kocaoglu, MD, Prof.
Department of Orthopedics and Traumatology, Faculty of Medicine, Acibadem Mehmet Ali Aydinlar University, Istanbul, Türkiye
Burak Akan, MD, Prof.
Department of Orthopedics and Traumatology, Ufuk University, School of Medicine, Ankara, Türkiye
Can Doruk Basa, MD, Assoc. Prof.
Department of Orthopaedics and Traumatology, Tepecik Training and Research Hospital, Izmir, Türkiye
Cemil Erturk, MD, Prof.
Department of Orthopaedics and Traumatology, Kanuni Sultan Süleyman Training and Research Hospital, University of Health Sciences, Istanbul, Türkiye
Derya Celik, PhD, Prof.
Department of Physiotherapy and Rehabilitation, Faculty of Health Sciences, Istanbul University-Cerrahpasa, Istanbul, Türkiye
Durmus Ali Ocguder, MD, Prof.
Yıldırım Beyazıt University, Ankara City Hospital, Department of Orthopedics and Traumatology, Antalya, Türkiye
Egemen Turhan, MD, Prof.
Hacettepe University, Medical Faculty, Department of Orthopedics and Traumatology, Ankara, Türkiye
Emin Bal, MD, Prof.
Izmir Tınaztepe University, Medical Faculty, Department of Orthopedics and Traumatology, Izmir, Türkiye
Emre Anil Ozbek, MD, Assoc. Prof.
Ankara University, Medical Faculty, Department of Orthopedics and Traumatology, Ankara, Türkiye
Emre Baca, MD, Assoc. Prof.
University of Health Sciences, Bakırköy Dr. Sadi Konuk Training and Research Hospital, Department of Orthopedics and Traumatology, Istanbul, Türkiye
Elcil Kaya Bicer, MD, Assoc. Prof.
Ege University, Medical Faculty, Department of Orthopedics and Traumatology, Izmir, Türkiye
Ertugrul Aksahin, MD, Prof.
Yuksek İhtisas University Medical School Orthopedics and Traumatology Department, Ankara, Türkiye
Gokhan Meric, MD, Prof.
Yeditepe University, Medical Faculty, Department of Orthopedics and Traumatology, Istanbul, Türkiye
Gokhan Polat, MD, Prof.
Istanbul University, Medical Faculty, Department of Orthopedics and Traumatology, Istanbul, Türkiye

STArt
TUSYAD
Sports Traumatology & Arthroscopy

Editorial Board

Gul Baltacı, PhD, Prof.
Atlas University, Faculty of Health Sciences, Department of Physiotherapy and Rehabilitation, Istanbul, Türkiye
Guzelali Ozdemir, MD, Prof.
Department of Orthopedics and Traumatology, Ankara Bilkent City Hospital, Ankara, Türkiye
Hakan Ozsoy, MD, Prof.
Clinic of Orthopaedic and Traumatology, Memorial Hospital, Ankara, Türkiye
Haluk Oztekin, MD, Prof.
Izmir Kent Hospital, Orthopaedics and Traumatology Clinic, Izmir, Türkiye
Hayri Baran Yosmaoglu, PhD, Prof.
Baskent University, Faculty of Health Sciences, Department of Physiotherapy and Rehabilitation, Ankara, Türkiye
Izzet Bingol, MD, Assoc. Prof.
Department of orthopedics and Traumatology, Health Sciences University, Faculty of Medicine, Ankara Oncology Training and Research Hospital, Ankara, Türkiye
John Nyland, MD, Prof.
Department of Orthopaedic Surgery, University of Louisville, Louisville, Kentucky, USA
Kerem Canbora, MD, Prof.
Uskudar University, Medical Faculty, Department of Orthopedics and Traumatology, Istanbul, Türkiye
Kursat Celik, PhD, Assoc. Prof.
Akdeniz University, Agricultural Faculty, Department Machinery and Technology Engineering, Antalya, Türkiye
Lena Sonnow, MD
Department of Diagnostic and Interventional Radiology, Hannover Medical School, Hannover, Germany
Levent Sarikcioglu, PhD, Prof.
Akdeniz University, Medical Faculty, Department of Anatomy, Antalya, Türkiye
Mahir Mahirogulları, MD, Prof.
Şişli Memorial Hospital, Department of Orthopedics and Traumatology, Istanbul, Türkiye
Mehmet Akif Altay, MD, Prof.
Department of Orthopedics and Traumatology, Medicine Faculty of Harran University, Sanlıurfa, Türkiye
Mehmet Emin Erdil, MD, Prof.
Department of Orthopaedics and Traumatology, Acibadem Maslak Hospital, Acibadem University, Istanbul, Türkiye
Meric Unal, MD, Assoc. Prof.
Private Meddem Hospital, Orthopedics and Traumatology Clinic, Isparta, Türkiye
Murat Cakar, MD, Assoc. Prof.
University of Health Sciences, Prof. Dr. Cemil Taşcıoğlu City Hospital, Department of Orthopedics and Traumatology, Istanbul, Türkiye
Mustafa Akkaya, MD, Assoc. Prof.
Ankara Yildirim Beyazit University, Ankara City Hospital, Ankara, Türkiye
Mustafa Citak, MD, PhD, Prof.
Department of Orthopedics and Traumatology, Helios ENDO-Klinik Hamburg, Holstenstr. 2, 22767, Hamburg, Germany
Muzaffer Sindel, PhD, Prof.
Akdeniz University, Medical Faculty, Department of Anatomy, Antalya, Türkiye
Nuri Aydin, MD, Prof.
Department of Orthopaedics and Traumatology, İstanbul University-Cerrahpaşa, Cerrahpaşa Faculty of Medicine, İstanbul, Türkiye
Nurzat Elmali, MD, Prof.
Department of Orthopedics and Traumatology, Bezmialem Foundation University School of Medicine, Istanbul, Türkiye
Omer Naci Ergin, MD, Assoc. Prof.
Istanbul University, Medical Faculty, Department of Orthopedics and Traumatology, Istanbul, Türkiye
Feza Korkusuz, MD, PhD, Prof.
Hacettepe University, Medical Faculty, Department of Sports Medicine, Ankara, Türkiye
Ramazan Akmese, MD, Prof.
Orthopedics and Traumatology Department, Haliç University, Istanbul, Türkiye
Safa Gursoy, MD, Assoc. Prof.
Acibadem University, Orthopedics and Traumatology, Department, Istanbul, Türkiye
Suleyman Semih Dedeoglu, MD, Prof.
Department of Orthopedics and Traumatology, Health Sciences University Baltalimanı Metin Sabancı Bone Diseases Training and Research Hospital, İstanbul, Türkiye
Tahsin Beyzadeoglu, MD, Prof.
Department of Orthopaedics & Traumatology, Halic University, Istanbul, Türkiye
Tekin Kerem Ulku, MD, Assoc. Prof.
Department of Orthopedic Surgery, Faculty of Medicine, Acibadem University, Istanbul, Türkiye

Biostatistics Editors

Andreas Ziegler, MD, PhD, Prof.
Cardio-CARE, Medizincampus Davos, Davos Wolfgang, Switzerland
Dilek Yapar, MD, PhD (cand.)
Turkish Ministry of Health, Muratpasa District Health Directorate, Antalya, Türkiye
Akdeniz University, Medical Faculty, Department of Biostatistics and Medical Informatics, Antalya, Türkiye

STArt
TUSYAD
Sports Traumatology & Arthroscopy

Aims & Scope

Sports Traumatology and Arthroscopy is an international, peer-reviewed journal dedicated to the latest advances and research in sports traumatology, arthroscopy and related surgical techniques. Our aim is to serve as a premier platform for the dissemination of significant new findings and the exchange of evidence-based knowledge and experience that highlight progress in all areas of sports traumatology and arthroscopy. Three issues are released every year in April, August, and December.

Aim

The primary aim of Sports Traumatology and Arthroscopy is to improve the care of patients with sports injuries by promoting the understanding of the pathophysiology of sports injuries, improving diagnostic techniques, and advancing treatment and rehabilitation methods. The journal aims to bridge the gap between sports traumatology research and clinical practice by providing a forum for the exchange of information relevant to clinical orthopedics, sports medicine and the science of sports injury and repair.

Scope of the Journal

The scope of the journal includes, but is not limited to, the following areas

Arthroscopy: Innovative techniques, clinical outcomes, and advances in arthroscopic surgery for the treatment of sports injuries.

Sports Orthopedics: Articles on surgical and non-surgical treatment options for sports injuries, including the use of novel techniques, materials, and implants.

Injury Prevention and Management: Studies on the prevention, diagnosis, treatment, and rehabilitation of sports-related injuries.

Regenerative Medicine: Treatment methods that involve the process of replacing, engineering, or regenerating human cells, tissues, or organs to restore or establish normal function after sports injuries, including ligaments, cartilage, menisci, and bone.

Biomechanics and Kinesiology: The study of the biomechanics of exercise and its effects on the body, with the goal of improving injury prevention strategies and rehabilitation approaches.

Rehabilitation and Physical Therapy: Evidence-based practices for rehabilitating athletes after injury or surgery, including physical therapy techniques and recovery protocols.

Performance Enhancement: Studies on optimizing athletic performance through innovative training techniques, nutrition, and injury prevention strategies.

Musculoskeletal Anatomy: Studies that focus on the anatomical and biomechanical aspects of sports injuries in order to develop better prevention and treatment strategies, such as new surgical techniques and modifications.

Diagnostic Techniques and Imaging: Research on imaging and diagnostic techniques for sports injuries.

Systematic Review and Metanalysis: Comprehensive reviews of the current literature that use explicit, systematic methods to identify, select, and critically appraise relevant research on a specific topic or question.

Case Reports: Detailed reports of individual cases, clinical experiences, and studies that contribute to the understanding of sports injuries and their management.

Sports Traumatology and Arthroscopy invites submissions from researchers, clinicians, and allied health professionals in sports medicine, orthopedic surgery, physical therapy, and related fields. We are committed to providing our readers with high-quality, impactful articles that contribute to the advancement of sports traumatology, arthroscopy, and injury management. Through rigorous peer review and a commitment to excellence, we aim to assist orthopedic surgeons and all physicians who care for patients with sports injuries in improving patient outcomes and advancing the field of sports traumatology and arthroscopy.

Owner: On behalf of the Turkish Sports Traumatology Arthroscopy and Knee Surgery Society: Prof.Dr. Yavuz KOCABEY
Address: 1420 Street No.67 Floor 1, Kahramanlar/İzmir: +90 (232) 463 00 36 Administrative Office: 2007 Street No.41 Beysukent/Çayyolu/Ankara; **Phone:** +90 (312) 988 02 68; **E-mail:** tusyad@tusyad.org

Publishing House: KARE Publishing; **Graphics Design:** Beste KURTCU
Address: Göztepe Mahallesi, Fahrettin Kerim Gökay Caddesi, No: 200, Daire: 2, Göztepe, Kadıköy, İstanbul, Türkiye; **Phone:** +90 216 550 61 11; **Fax:** +90 216 550 61 12; **E-mail:** kare@karepb.com

Instructions for the Authors

Preparation of Manuscripts

The Language

STArt's official language is English. STArt accepts manuscripts written in clear and understandable English, either American or British style. It is strongly recommended that authors who feel that their English language may need correction seek editing and proofreading services.

Manuscript Submission

Please submit your manuscript documents using the "Manuscript Submission" link on the home page. Before submitting, please make sure that all required documents are ready to be uploaded. The submission checklist available from the home page menu 'Author Form' can be used as a guide.

Document Formatting

The main text and tables must be submitted in Microsoft Word document format (.doc or .docx), using 11 pt Times New Roman font, with the main text double-spaced and 2.5 cm margins. Please do not use headers, footers, or endnotes in your paper. Use automatic page numbering to number the pages.

Title Page

This journal follows a blinded peer-review process. Reviewers are blinded to the authors of the paper. Therefore, authors are expected to submit a separate title page. The title page should contain the following information;

Title of the manuscript

All authors' names in order of sequence (Name and Surname)

Academic degree of authors (MD, PhD, Prof.... etc.)

ORCID number (Please see below or refer to https://orcid.org/)

Affiliations of the authors

Contact information of the corresponding author

The name of the **department and institution** in which the work was done

Declarations

Acknowledgments

Ethics approval and consent to participate: The name of the ethical committee or institutional review board, Date of approval, and the number of approvals.

Informed Consent: Conflict of interest statement:

Funding: Availability of data and material.

Authors' contributions: The title page template can be downloaded from the Author Forms at the journal's website.

Attention!

Authors are expected to consider the list of authors carefully before submitting their manuscript and provide the definitive list of authors at the time of the original submission. Any addition, deletion, or rearrangement of author names in the authorship list is not accepted after the submission or during the revisions.

ORCID

ORCID IDs of all authors must be stated during the submission of the manuscript. All IDs will be linked to the authors' pages at https://orcid.org in an online PDF, and the ID of the corresponding author will be added to the details. ORCID IDs will prevent the confusion caused by name similarities and affiliations. All authors can create free accounts on https://orcid.org and get a personal 16-digits number. ORCID also increases the visibility of author and their works by keeping profiles up-to-date.

Abstract

For original articles, a structured abstract of a maximum of 350 words must be submitted on a separate page. The abstract should contain sections describing **the purpose, materials and methods, results, and conclusions**. For case reports, an unstructured abstract of a maximum of 300 words must be submitted.

Keywords

4-6 keywords should be provided for each type of manuscript. Keywords should be chosen from Medical subject headings (MeSH) terms (Please refer to https://www.ncbi.nlm.nih.gov/mesh/)

Level of Evidence

The journal requires authors to categorize all manuscripts with a clinical focus according to the level of evidence. You can find the level of evidence table in the Author Forms Section on the journal page.

Manuscript Text

The main text and tables must be sent in Microsoft Word document format (.doc or .docx), with 11 pt Times New Roman font. The main text should be double-spaced with 2.5cm margins. Please do not use headers, footers, or endnotes in your paper. Use the automatic

page numbering function to number the pages. The text of an original article should be divided into the following paragraphs: **Introduction, Materials and Methods, Results, Discussion, and Conclusions**.

Every research paper should adhere to appropriate standards for research reporting. This ensures that editors, peer reviewers, and readers have sufficient information to understand the research methodology and assess the reliability of the results. We recommend the use of standard reporting templates for various studies, which you can find at https://www.equator-network.org/.

Preparation of Declarations in the Abstract Page

Acknowledgements

List all contributors who do not meet the criteria for authorship, such as technical assistants, assistants in data collection and entry, illustrators, writing assistants, or heads of departments who provided only general support. Financial and other material support should be disclosed and acknowledged.

Author Contribution Statement

All authors' contributions to the manuscript should be listed under the authors' contribution categories using their initials (e.g., ML). It should also be noted that all authors have read the final version of the submitted manuscript and agree with its accuracy.

Ethical Approval and Consent to Participate

The institution from which the ethics committee approval was obtained and the date and number of the approval should be reported. For studies where ethics committee approval is not required, the reason why it is not required should be reported. It should also be stated that informed consent was obtained from the participants.

Funding Statement

All authors are required to declare what support they received to carry out their research. Declaring funding sources acknowledges funders' contributions, fulfills funding requirements, and promotes greater transparency in the research process. Each author must individually declare all sources of funding received for the research submitted to the journal. This information includes the name of granting agencies, grant numbers, and a description of each funder's role. If the funder has played no role in the research, this must be stated as well. If no financial support was received, it should be written as 'No financial support was received for this study'.

Conflicts of Interest

Authors are asked to declare any interests that are directly or indirectly related to the work they are submitting for publication. They should report any interests for the past three years from the time the research was conducted and the manuscript was prepared for submission. Any interests beyond this three-year period must also be disclosed if they could potentially be seen as influencing the submitted work. This practice of disclosing interests ensures a transparent and comprehensive process that helps readers make informed judgments about potential bias. It's important to note that disclosure of financial relationships with a sponsoring organization or compensation for consulting does not imply that such relationships are improper.

Data Availability Statement

A data availability statement in an article informs readers about the location and method of accessing data underpinning the findings and analyses. This might encompass links to datasets that are open to the public and were examined or created as part of the research, details about the available data, and/or instructions for obtaining data that isn't openly accessible. We strongly recommend uploading the raw data as a Supplementary file.

References

General Guidelines

Authors should always try to read and cite the original work (the primary source) in the manuscript. In cases where this is not possible, secondary sources citing the primary original source may be cited. However, this situation is undesirable and should be used unexceptionally. Self-citations may be used if the content of the article is related to the submitted manuscript. However, authors, editors, and peer-reviewers should not abuse this option to promote their own papers.

Unpublished studies, unpublished observations, personal communications, and retracted papers cannot be cited. Citations from the predatory or pseudo-journals should be avoided. Please refer to the following list of possible such journals using this link. https://beallslist.net/.

There is no limit to the number of references. However, authors should cite only the necessary articles.

Style and Format

Reference citations in the text should be identified by numbers in square brackets, such as [5], [7,8], and [4-9, 11]. The reference list should be numbered consecutively.

Journal Article

Grimberg J, Duranthon LD, Bellaïche L, Petrover D, Kalra K. The time for functional recovery after arthroscopic rotator cuff repair: Correlation with tendon healing controlled by computed tomography arthrography. Arthroscopy. 2008;24:25-33.

If there are more than 6 authors, provide first six authors and use 'et al.' at the end of author list. Digital Object Identifier (doi) number should be added to the end of the reference (if available).

Cvetanovich GL, Gowd AK, Liu JN, Nwachukwu BU, Cabarcas BC, Cole BJ, et al. Establishing clinically significant outcome after arthroscopic rotator cuff repair. J Shoulder Elbow Surg. 2019;28:939-48.

Book

Newton ML. Current practice of pain. 1st ed. St. Luis, MO: Mosby; 1990.

Book Chapter

Jurkovich GJ. Duodenum and pancreas. In: Mattox KL, Feliciano DV, Moore EE, editors. Trauma. 4th ed. New York: McGraw-Hill; 2000. pp. 735-62.

Online Document

Cartwright J. Big stars have weather too. IOP Publishing PhysicsWeb. http://physicsweb.org/articles/news/11/6/16/1. Accessed 26 June 2007.

Dissertation

Trent JW. Experimental acute renal failure. Dissertation, University of California; 1975.

Case Reports

New, interesting and rare cases can be reported. They should be unique, describing a great diagnostic or therapeutic challenge and providing a learning point for the readers. Cases with clinical significance or implications will be given priority. These communications could be of up to 1500 words (excluding Abstract and references) and should have the following headings: Abstract (unstructured), Key-words, Introduction, Case report, Discussion, Reference, Tables and Legends in that order. The manuscript could be of up to 1500 words (excluding references and abstract) and could be supported with up to 20 references. Case Reports could be authored by up to 4 authors.

Letter to the Editor

We welcome letters offering commentary on articles we have recently published. This may include constructive criticism, additional insights, related experiences, or discussions that further the conversation initiated by the original article. Letters to the Editor should be concise, focused, and articulate clear points of discussion. While these submissions undergo a peer-review process, they are streamlined compared to full research articles, emphasizing relevance, accuracy, and the potential to contribute constructively to our readers' understanding and engagement.

Tables

All tables should be prepared in Microsoft Word document format (.doc or .docx) and numbered using Arabic numerals. They should be cited consecutively in the text. Each table should have a title or caption that explains its content. Any footnote that contributes to ease the understanding of the table may be added beneath the table body.

Figures

All figures should be properly numbered and uploaded as separate files. Name the figure files accordingly. Cite all figures in the order they appear in the text within parenthesis, such as (Figure 1). Figures with multiple parts should be marked a, b, c, etc., with a description of each panel included in the legend rather than on the figure. Figures must be submitted in **TIFF format**. Color or grayscale photographs should be saved at a minimum of **300 dpi** or higher. Electronic artworks or illustrations should be saved at a minimum of **1200 dpi** or higher. The size of the figure should fit either in one, one and half, or two columns in width (1 column: 8.9 cm, 1.5 columns: 12 cm, two columns: 18 cm in width).

Authors wishing to include figures, photographs, illustrations, diagrams, charts, etc., that have already been published in another journal or book are required to obtain written permission from the copyright owner(s) for both the print and online format and to include evidence that such permission has been granted when submitting their papers. Any document received without permission will be assumed to originate from the authors.

Figure Legends

Figure legends for all images must be included at the end of the manuscript text file, after the References section. Explain what each figure shows. Identify machine settings for magnetic resonance and computed tomography images and give the magnification of all photomicrographs. Define all arrows and other such indicators appearing on the figure.

Abbreviations and Symbols

Use only standard abbreviations; using nonstandard abbreviations can be confusing to readers. Avoid abbreviations in the manuscript's title. The spelled-out abbreviation followed by the abbreviation in parenthesis should be used on the first mention unless the abbreviation is a standard unit of measurement. A list of abbreviations should be included in the manuscript text.

Units of Measurements

Measurements of length, height, weight, and volume should be reported in metric units (meter, kilogram, or liter) or their decimal multiples. Temperatures should be in degrees Celsius, and blood pressure should be in millimeters of mercury unless the journal specifically requires other units. Journals vary in the units they use for reporting hematologic, clinical chemistry, and other measurements. Authors must consult the Information for Authors of the particular journal and should report laboratory information in both local and International Systems of Units (SI). Editors may request that authors add alternative or non-SI units since SI units are not universally used. Drug concentrations may be reported in either SI or mass units, but the alternative should be provided in parentheses where appropriate.

Permissions

Authors wishing to include previously published figures, tables, or excerpts in their manuscripts must obtain permission from the copyright holders for both print and digital publication. They must also provide proof of such permission at the time of submission. Failure to provide such proof will result in the material being assumed to be the author's original work.

Ethics & Policies

Advertisement Policy

The Sports Traumatology and Arthroscopy does not accept advertisements; the journal is sponsored by the Turkish Sports Traumatology Arthroscopy and Knee Surgery Society.

Authorship Policy

All statements and opinions expressed in the manuscripts published in the Sports Traumatology and Arthroscopy reflect the views of the author(s).

Each individual listed as an author should fulfill the authorship criteria recommended by the International Committee of Medical Journal Editors (ICMJE). The ICMJE recommends that authorship should be based on the following 4 criteria:

Substantial contributions to the conception or design of the work, or the acquisition, analysis, or interpretation of data for the work; AND

Drafting the work or revising it critically for important intellectual content; AND

Final approval of the version to be published; AND

Agreement to be accountable for all aspects of the work in ensuring that questions related to the accuracy or integrity of any part of the work are appropriately investigated and resolved.

In addition to being accountable for their own work, authors should have confidence in the integrity of the contributions of their co-authors and each author should be able to identify which co-authors are responsible for other parts of the work.

All of those designated as authors should meet all four criteria for authorship, and all who meet the four criteria should be identified as authors. Those who provided a contribution but do not meet all four criteria should be recognized separately on the title page and in the Acknowledgements section at the conclusion of the manuscript.

The Sports Traumatology and Arthroscopy requires that corresponding authors submit a signed and scanned version of the authorship contribution form (available for download through) during the initial submission process in order to appropriately indicate and observe authorship rights and to prevent ghost or honorary authorship. Please note that the list of authors on the final manuscript will be presented in the order provided on this form. If the editorial board suspects a case of “gift authorship,” the submission will be rejected without further review. As part of the submission of the manuscript, the corresponding author should also send a short statement declaring that they accept all responsibility for authorship during the submission and review stages of the manuscript.

Complaint and Appeal Policy

Appeal and complaint cases are handled within the scope of COPE guidelines by the Editorial Board of the journal. Appeals should be based on the scientific content of the manuscript. The final decision on the appeal and complaint is made by Editor in Chief. An Ombudsperson or the Ethical Editor is assigned to resolve cases that cannot be resolved internally. Authors should get in contact with the Editor in Chief regarding their appeals and complaints via e-mail at kare@karepb.com

Corrections Policy

If the editors or publisher learn from a third party that a published work contains a material error or inaccuracy, the authors must promptly correct or retract the article or provide the journal editors with evidence of the accuracy of the article.

Ethics Policy

The Editorial Board of the Sports Traumatology and Arthroscopy and the Publisher adheres to the principles of the International Council of Medical Journal Editors (ICMJE), the World Association of Medical Editors (WAME), the Council of Science Editors (CSE), the Committee on Publication Ethics (COPE), the US National Library of Medicine (NLM), the World Medical Association (WMA) and the European Association of Science Editors (EASE).

In accordance with the journal’s policy, an approval of research protocols by an ethics committee in accordance with international agreements “WMA Declaration of Helsinki - Ethical Principles for Medical Research Involving Human Subjects (last updated: October 2013, Fortaleza, Brazil)”, “Guide for the care and use of laboratory animals (8th edition, 2011)” and/or “International Guiding Principles for Biomedical Research Involving Animals (2012)” is required for all research studies. If the submitted manuscript does not include ethics committee approval, it will be reviewed according to COPE’s guideline (Guidance for Editors: Research, Audit and Service Evaluations). If the study should have ethical approval, authors will be asked to provide ethical approval in order to proceed the review process. If they cannot provide ethical approval, their manuscript will be rejected and also their institutions and when needed, the related bodies in their country will be informed that such studies must have ethics committee approval. If they provide approval, review of the manuscript will continue.

If the study does not need ethics committee approval after the editorial board’s review, the authors will be asked to provide an ethics committee approval or a document given by a related independent committee that indicates the study does not need ethics committee approval according to the research integrity rules in their country. If the authors provide either an approval or a document showing that ethics approval is not needed, the review process can be continued. If the authors cannot provide either documents, the manuscript may be rejected.

For articles concerning experimental research on humans, a statement should be included that shows informed consent of patients and volunteers was obtained following a detailed explanation of the procedures that they may undergo. The journal may request a copy of the Ethics Committee Approval received from the relevant authority. Informed consent must also be obtained for case reports and clinical images.

Studies using human or animal subjects should be approved by the appropriate institutional and local Ministry of Health ethics committees. Ethics approval of research protocols in accordance with international agreements is required for experimental, clinical, and drug studies, as well as for some case reports. Ethics committee reports or an equivalent official document may be requested from the authors. For manuscripts involving experimental research on humans, a statement should be included that shows that written, informed consent of patients and volunteers was obtained. For studies carried out on animals, the measures taken to prevent pain and suffering of the animals should be stated clearly. A statement regarding patient consent, and the name of the ethics committee, the ethics committee approval date, and number should be stated in the Materials and Methods section of the manuscript. It is the authors' responsibility to carefully protect patients' anonymity.

Fee Waiver Policy

There is no fee waiver.

Funding Sources Policy

All authors are required to declare what support they received to carry out their research. Declaring funding sources acknowledges funders' contributions, fulfills funding requirements, and promotes greater transparency in the research process.

Each author must individually declare all sources of funding received for the research submitted to the journal. This information includes the name of granting agencies, grant numbers, and a description of each funder's role. If the funder has played no role in the research, this must be stated as well.

Authors are not required to provide the complete list of every single grant that supports them if the grant is not related to the research published.

Licenses and Copyright Policy

Authors publishing with the journal retain the copyright to their work licensed under the Creative Commons Attribution-NonCommercial 4.0 International license (CC BY-NC 4.0) and grant the Publisher non-exclusive commercial right to publish the work. CC BY-NC 4.0 license permits unrestricted, non-commercial use, distribution, and reproduction in any medium, provided the original work is properly cited.

Open Access Policy

The Sports Traumatology and Arthroscopy supports the Budapest Open Access Initiative statement of principles that promotes free access to research literature. The declaration defines open access to academic literature as free availability on the internet, permitting users to read, record, copy, print, search, or link to the full text, examine them for indexing, use them as data for software or other lawful purposes without financial, legal, or technical barriers. Information sharing represents a public good, and is essential to the advancement of science. Therefore, articles published in this journal are available for use by researchers and other readers without permission from the author or the publisher provided that the author and the original source are cited. The articles in the Sports Traumatology and Arthroscopy are accessible through search engines, websites, blogs, and other digital platforms. Additional details on the Budapest Open Access Initiative and their guidelines are available at https://www.budapestopenaccessinitiative.org.

Open Access Policy is based on rules of Budapest Open Access Initiative the Sports Traumatology and Arthroscopy applies the Creative Commons Attribution-NonCommercial 4.0 International (CC BY-NC 4.0) license to articles we publish. If you submit your paper for publication, you agree to have the CC BY-NC 4.0 license applied to your work. Under this Open Access license, you as the author agree that anyone can copy, distribute or reuse the content of your article for non-commercial purposes for free as long as the author and original source are properly cited. The corresponding author must sign the Creative Commons License Agreement after their articles are accepted.

Open Access Statement

The journal is an open access journal and all content is freely available without charge to the user or his/her institution. Except for commercial purposes, users are allowed to read, download, copy, print, search, or link to the full texts of the articles in this journal without asking prior permission from the publisher or the author. This is in accordance with the BOAI definition of open access. The open access articles in the journal are licensed under the terms of the Creative Commons Attribution-NonCommercial 4.0 International (CC BY-NC 4.0) license.

Peer Review Policy

Only those manuscripts approved by its every individual author and that were not published before in or sent to another journal, are accepted for evaluation.

Submitted manuscripts that pass preliminary control are scanned for plagiarism using iThenticate software. After plagiarism check, the eligible ones are evaluated by Editor-in-Chief for their originality, methodology, the importance of the subject covered and compliance with the journal scope. Editor-in-Chief evaluates manuscripts for their scientific content without regard to ethnic origin, gender, sexual orientation, citizenship, religious belief or political philosophy of the authors and ensures a fair double-blind peer review of the selected manuscripts.

The selected manuscripts are sent to at least two national/international referees for evaluation and publication decision is given by Editor-in-Chief upon modification by the authors in accordance with the referees' claims.

Editor-in-Chief does not allow any conflicts of interest between the authors, editors and reviewers and is responsible for final decision for publication of the manuscripts in the Journal.

Reviewers' judgments must be objective. Reviewers' comments on the following aspects are expected while conducting the review.

- Does the manuscript contain new and significant information?
- Does the abstract clearly and accurately describe the content of the manuscript?
- Is the problem significant and concisely stated?
- Are the methods described comprehensively?
- Are the interpretations and consclusions justified by the results?
- Are adequate references made to other Works in the field?
- Is the language acceptable?

Reviewers must ensure that all the information related to submitted manuscripts is kept as confidential and must report to the editor if they are aware of copyright infringement and plagiarism on the author's side.

A reviewer who feels unqualified to review the topic of a manuscript or knows that its prompt review will be impossible should notify the editor and excuse himself from the review process.

The editor informs the reviewers that the manuscripts are confidential information and that this is a privileged interaction. The reviewers and editorial board cannot discuss the manuscripts with other persons. The anonymity of the referees is important.

Plagiarism Policy

All submissions are screened using similarity detection software at least two times: on submission and after completing revisions. In the event of alleged or suspected research misconduct, e.g., plagiarism, citation manipulation, or data falsification/fabrication, the editorial board will follow and act in accordance with COPE guidelines. Plagiarism, including self-plagiarism, that is identified at any stage will result in rejection of the manuscript.

Publication Charges Policy

The Sports Traumatology and Arthroscopy assesses no submission fees, publication fees, or page charges.

Retraction Policy

The publisher will take all appropriate measures to modify the article in question, in close cooperation with the editors, in cases of alleged or proven scientific misconduct, fraudulent publication, or plagiarism. This includes the prompt publication of an erratum, disclosure, or retraction of the affected work in the most severe case.

Together with the editors, the publisher will take reasonable steps to detect and prevent the publication of articles in which research misconduct occurs and will under no circumstances promote or knowingly allow such abuse to occur.

Withdrawal Policy

The Sports Traumatology and Arthroscopy is committed to providing high quality articles and uphold the publication ethics to advance the intellectual agenda of science. We expect our authors to comply with, best practice in publication ethics as well as in quality of their articles.

Withdrawal of a manuscript will be permitted only for the most compelling and unavoidable reasons. For withdrawal of a manuscript authors need to submit an "Article withdrawal Form", signed by all authors mentioning the reason for withdrawal to the Editorial Office. Authors must not assume that their manuscript has been withdrawn until they have received appropriate notification to this effect from the editorial office.

In a case where a manuscript has taken more than five months' time for review process, that allows the author to withdraw manuscript.

Manuscript withdrawal penalty: After receiving the Article withdrawal Form, the Sports Traumatology and Arthroscopy Editorial Board will investigate the reason of withdrawal.

If the reason finds to be acceptable, the author is allowed to withdraw the manuscript without any withdrawal penalty. If not the Sports Traumatology and Arthroscopy will not accept any manuscripts from the same author for one year.

Important notes: Manuscripts may be withdrawn at any stage of review and publication process by submitting a request to the editorial office. Manuscript withdrawal will be permitted after submission only for the most compelling and unavoidable reasons.

If the author wants to withdraw a manuscript, the author needs to submit a completed "Article withdrawal Form", signed by all authors of the manuscript stating the reasons for manuscript withdrawal.

The manuscript will not be withdrawn from publication process until a completed, signed form is received by the editorial office. Authors must not assume that their manuscript has been withdrawn until they have received appropriate notification to this effect from the Sports Traumatology and Arthroscopy editorial office.

STArt
TUSYAD

Sports Traumatology & Arthroscopy

Volume: 1 Issue: 1 Year: 2024

Contents

Editorial

STArt Has Just Started 1
O. Kose

Original Articles

Nanofat Grafts Enhance Tendon Healing in a Chronic Achilles Tendinopathy Rat Model 3
A. Bicer, K. Kayikci, O. F. Demir, C. Tomruk, Y. Uyanikgil, E. Kaya Bicer

Efficacy of Retrograde Bone Grafting for Cystic Osteochondral Lesions of the Tibial Plafond: A Retrospective Study 14
M. B. Ertan, H. Selcuk, H. Cetin, F. Dogruoz, O. F. Egerci

Comparison of Two Different Intraarticular Hyaluronic Acid Injection Regimens in Knee Osteoarthritis: A Randomized Clinical Trial 24
A. Bozdemir, M. Unal, M. B. Ertan, O. F. Egerci

Reviews

Surgical Treatment of Symptomatic Bipartite Patella: A Case Report and Review of the Current Literature 33
M. Yuncu, O. F. Egerci, F. Dogruoz

How to Avoid Iatrogenic Saphenous Nerve Injuries during Hamstring Tendon Harvesting: A Narrative Review 43
I. Bingol, A. Yapar, E. Veizi, H. A. Olcar, M. F. Catma, O. Pekince, M. B. Ataoglu

STArt
Sports Traumatology & Arthroscopy
TUSYAD
DOI: 10.14744/start.2024.09168
Sports Traumatol Arthrosc 2024;1(1):1-2

Editorial

STArt Has Just Started

Ozkan Kose

Department of Orthopedics and Traumatology, University of Health Sciences, Antalya Training and Research Hospital, Antalya, Türkiye

It is with great excitement that we present the first issue of Sports Traumatology and Arthroscopy (STArt), a journal dedicated to advancing the fields of sports traumatology, arthroscopy, and associated disciplines. STArt has just started its journey. Our mission is to serve as a platform for evidence-based research, fostering collaboration and innovation among clinicians, researchers, and healthcare professionals worldwide. In today's rapidly evolving landscape of sports medicine and orthopedics, the demand for cutting-edge diagnostic techniques, advanced surgical approaches, and comprehensive rehabilitation protocols has never been greater. As sports participation grows and new challenges arise, we must remain steadfast in our commitment to enhancing patient care and improving outcomes. With this in mind, Sports Traumatology and Arthroscopy aim to bridge the gap between scientific research and clinical practice, providing readers with a rich source of knowledge that is both accessible and applicable.

Turkish Sports Traumatology Arthroscopy and Knee Surgery Society (TUSYAD) was officially established on June 30, 1988. For over 36 years, this esteemed society has become one of Türkiye's most significant professional organizations, with over 1,000 active members who continue to contribute dynamically to the field. The launch of STArt marks a crucial milestone aimed at publishing the scientific output of this vast and accomplished community and setting a new benchmark in the dissemination of sports traumatology research.

Our journal will cover a broad spectrum of topics, from injury prevention and biomechanics to performance enhancement and regenerative medicine. We welcome submissions in the form of original research articles, systematic reviews, case reports, and technical notes. Contributions from experts in sports medicine, orthopedic surgery, physical therapy, and related disciplines are especially valued. Each submission will undergo a rigorous peer-review process to ensure the highest standards of quality and scientific integrity.

Beyond merely publishing research, we aspire to shape the future of sports traumatology and arthroscopy. By facilitating an exchange of ideas and fostering an environment of collaboration, we hope to drive the development of innovative solutions that enhance the well-being of athletes and active individuals. Our vision extends beyond the immediate impact of each article, aiming instead to cultivate a community that champions evidence-based practices and continuous learning.

We would like to express our heartfelt gratitude to the Turkish Sports Traumatology Arthroscopy and Knee Surgery Society (TUSYAD) for their unwavering support in establishing this journal. In particular, we extend our deepest thanks to President Prof. Dr. Yavuz Kocabey and the entire executive board for their dedication and encouragement, which have been instrumental in bringing this vision to life.

Cite this article as:
Kose O. STArt Has Just Started. Sports Traumatol Arthrosc 2024;1(1):1-2.

Address for correspondence:
Ozkan Kose.
Department of Orthopedics and Traumatology, University of Health Sciences, Antalya Training and Research Hospital, Antalya, Türkiye
E-mail:
drozkankose@hotmail.com

Available Online: 28.11.2024

Sports Traumatology & Arthroscopy – Available online at www.stajournal.com

This work is licensed under a Creative Commons Attribution-NonCommercial 4.0 International License.

We invite you to engage with Sports Traumatology and Arthroscopy as both contributors and readers. Your research, insights, and expertise are crucial to the growth and success of this journal. Together, we can push the boundaries of our field, making meaningful strides toward better diagnostics, more effective treatments, and improved rehabilitation strategies.

Thank you for your support and belief in our vision. We look forward to embarking on this journey with you and witnessing the remarkable advances that will undoubtedly unfold. I welcome you to Sports Traumatology and Arthroscopy on behalf of the entire editorial team.

Sincerely,

Editor-in-Chief

STArt
Sports Traumatology & Arthroscopy
DOI: 10.14744/start.2024.73736
Sports Traumatol Arthrosc 2024;1(1):3-13

Original Article

Nanofat Grafts Enhance Tendon Healing in a Chronic Achilles Tendinopathy Rat Model

Ahmet Bicer,[1] Kayahan Kayikci,[2] Orhan Fahri Demir,[3] Canberk Tomruk,[4] Yigit Uyanikgil,[5] Elcil Kaya Bicer[6]

[1]Department of Plastic Reconstructive and Aesthetic Surgery, Ege University Faculty of Medicine, Izmir, Türkiye
[2]Department of Orthopedics and Traumatology, Kastamonu Training and Research Hospital, Kastamonu, Türkiye
[3]Department of Plastic Reconstructive and Aesthetic Surgery, Istinye University Bahcesehir Liv Hospital, Istanbul, Türkiye
[4]Department of Histology and Embryology, Samsun Training and Research Hospital, Samsun, Türkiye
[5]Department of Histology and Embryology, Ege University Faculty of Medicine, Izmir, Türkiye
[6]Department of Orthopedics and Traumatology, Ege University Faculty of Medicine, Izmir, Türkiye

Cite this article as:
Bicer A, Kayikci K, Demir OF, Tomruk C, Uyanikgil Y, Kaya Bicer E, et al. Nanofat Grafts Enhance Tendon Healing in a Chronic Achilles Tendinopathy Rat Model. Sports Traumatol Arthrosc 2024;1(1):3-13.

Address for correspondence:
Elcil Kaya Bicer.
Department of Orthopedics and Traumatology, Ege University Faculty of Medicine, Izmir, Türkiye
E-mail: elcil@yahoo.com

Submitted: 10.10.2024
Revised: 24.10.2024
Accepted: 24.10.2024
Available Online: 28.11.2024

Sports Traumatology & Arthroscopy – Available online at www.stajournal.com

This work is licensed under a Creative Commons Attribution-NonCommercial 4.0 International License.

ABSTRACT

Objective: Chronic tendinopathy is a prevalent condition with long recovery times, often necessitating treatments beyond conventional methods like rest and stretching. This study aimed to evaluate the regenerative and anti-inflammatory effects of nanofat and microfat grafts in a collagenase-induced rat model of Achilles tendinopathy.

Materials and Methods: Using collagenase injections, a chronic Achilles tendinopathy model was induced in 27 Wistar albino rats. The rats were randomly divided into three groups: Group 1 received microfat grafts, Group 2 received nanofat grafts, and Group 3 (control) received phosphate-buffered saline (PBS). Nanofat and microfat grafts were prepared from the inguinal fat pads of the rats. Histological and immunohistochemical analyses were performed 12 weeks after treatment.

Results: The nanofat group exhibited significantly lower Modified Verhofstad scores compared to the control group, particularly for fibrosis, polymorphonuclear leukocyte (PMNL) infiltration, edema, collagen, and fibroblast density ($p<0.016$). Both the nanofat and microfat groups demonstrated significantly higher vascularity compared to the control group ($p<0.016$). The nanofat group showed significantly less PMNL infiltration, edema, and greater collagen density than the microfat group ($p<0.016$). Immunohistochemistry revealed the highest immunopositivity for type I and type III collagen in the nanofat group, while the control group showed the lowest levels. CD45 immunoreactivity was most diffuse in the control group and minimal in the nanofat group.

Conclusion: Nanofat, enriched with mesenchymal stem cells and growth factors, significantly improved histopathological outcomes and reduced inflammation compared to microfat and control treatments in a chronic Achilles tendinopathy rat model. These findings suggest that nanofat grafts may offer a minimally invasive and effective treatment for chronic tendinopathy.

Keywords: Achilles tendon, adipose-derived mesenchymal stem cell, microfat, nanofat, regenerative medicine, stem cell treatment, tendinitis, tendinopathy, tendinosis

INTRODUCTION

Tendinopathies, or tendonitis, are relatively common musculoskeletal conditions that typically result from repetitive overuse or forced activity. They mainly present as tenderness and pain in and around the affected tendon. This condition can lead to a loss of work hours/days for productive individuals, particularly those with active lifestyles. It may even result in premature retirement from sports or related professions [1]. Although common, the underlying pathological mechanisms remain poorly understood [2]. As a result, no treatment method has consistently demonstrated efficacy in the current literature [3]. While inflammatory processes play a more prominent role in the early stages of the disease, the chronic phase is marked by an imbalance between collagen production and degradation, particularly in the ratio of type III collagen to type I collagen [1].

The most common treatment methods are rest, strengthening, and stretching exercises [1, 3]. However, the prolonged duration of rest and the intensity of exercises can make it challenging for patients to adhere to treatment. Medical options include steroid injections and nonsteroidal anti-inflammatory drugs (NSAIDs), but these present two significant issues: first, inflammatory processes have not been conclusively proven to be central in the disease mechanism, and second, steroid injections are associated with adverse effects, such as reduced tendon rupture resistance and inhibited collagen synthesis [4, 5]. As a result, new treatment strategies that control pain while preserving tendon integrity are needed [6].

Recent advancements in regenerative medicine have led to experimental treatments such as platelet-enriched plasma (PRP) injections and bone marrow (BMSC) or mesenchymal stem cell (MSC) therapies [7]. PRP has been widely studied as a source of autologous growth factors and immunomodulators, including bFGF, TGF-ß, and BMP-12 [7-9]. Adipose tissue is now recognized as a promising source of MSCs, with adipose-derived stem cells (ASCs) offering advantages over BMSCs due to better accessibility and safety profiles [10]. The composition of fat tissue grafts, including mature adipocytes, MSCs, and growth factors, varies depending on the harvesting and processing methods. Additionally, adipose tissue is a known source of extracellular vesicles or exosomes, which serve as carriers of growth factors or RNA fragments that encode pro-regenerative proteins [11].

In terms of cellular composition, structural fat grafts (unprocessed macro-fat) contain the highest number of cells, predominantly adipocytes. Microfat grafts, which undergo moderate emulsification, contain fewer adipocytes and relatively more MSCs. Nanofat grafts, created through more vigorous emulsification, contain no intact adipocytes but include MSCs and higher concentrations of growth factors, exosomes, chemokines, and cytokines [12]. In summary, less processed fat grafts (such as structural and microfat) are typically used for volume reconstruction, whereas nanofat grafts are primarily employed for regenerative purposes [12].

In this experimental study, we investigated the effectiveness of nanofat grafts compared to control and microfat injection groups in a rat model of Achilles tendinopathy. Specifically, we aimed to determine whether nanofat and microfat injections promoted histological recovery in treating collagenase-induced tendinopathy in rats. We hypothesized that nanofat grafts, with their higher concentrations of mesenchymal stem cells (MSCs) and stromal vascular fraction-derived growth factors, would result in significantly better histological recovery and reduced inflammation compared to microfat grafts and control treatments.

MATERIALS AND METHODS

Animals and Study Design

This experimental study involved 27 adult male Wistar albino rats (8–10-weeks-old), each weighing between 250 and 330 grams. The rats were provided with a standard laboratory diet and had unrestricted access to water. They were housed in individual standard cages in a temperature-controlled environment maintained at 20-22°C. Before the commencement of the experiment, approval was obtained from the Ege University Animal Experiments Local Ethics Committee (approval date/issue: 28.05.2020/055), and the study was conducted at the institution's Center for Experimental Animals. This study was conducted in accordance with the ARRIVE (Animal Research: Reporting of In Vivo Experiments) guidelines to ensure robust and transparent reporting of animal research [13].

Collagenase-induced Achilles Tendinopathy Model

The chronic tendinopathy model chosen for this study was the chemical method using collagenase, originally developed by Silver et al. for equine models; this model has since been further refined for use in rats with a predictable time course by Orfei et al. [14]. They found that a concentration of 3 mg/mL of collagenase (high dose) and a minimum waiting period of two weeks was required to produce a chronic tendinopathy similar to that seen in humans. We followed this protocol in our study, except they used Sprague-Dawley rats in their experiment, whereas we used Wistar-albino rats.

General anesthesia was administered using a mixture of Ketamine HCl (80-100 mg/kg) and Xylazine HCl (10-12.5 mg/kg). Analgesic and antibiotic prophylaxis, including paracetamol and cefazoline, were provided before the surgical procedure. A 1 cm longitudinal incision was made along the posterior border of the right ankle, and 30 µL of 3 mg/mL type I collagenase (derived from Clostridium histolyticum, Sigma

Aldrich™, St. Louis, MO, USA), diluted with phosphate-buffered saline to a total volume of 1 mL, was injected directly into the tendon using a 26 G needle.

Preparation and Administration of Nanofat and Microfat

On the 14th day post-collagenase injection, the animals were randomly divided into three groups: 1) Group I: microfat, 2) Group II: nanofat, and 3) Group III: control. All rats were anesthetized, scrubbed, and prepared for surgery similarly. The inguinal fat pads were excised for use in the microfat and nanofat groups, while PBS was used in the control group (Fig. 1a). Microfat group: In nine rats, the excised fat pads were minced with surgical scissors and emulsified with phosphate-buffered saline (PBS). The emulsified tissue was passed 20 times through a 2.4 mm Luer-lock cannula to achieve limited thinning. The prepared microfat graft was injected into the right Achilles tendon through the initial posteromedial incision. Nanofat group: The same procedure as the microfat group was followed for another nine rats, except the emulsified tissue was additionally passed 100 times through a smaller 1.2 mm Luer-lock cannula and filtered through a 0.1 mm strainer to prepare the nanofat graft (Fig. 1b). This graft was injected into the right Achilles tendon through the same posteromedial incision (Fig. 1c). Control group: In the control group of nine rats, following the excision of the inguinal fat pads, PBS was injected into the right Achilles tendon through the initial posteromedial incision.

Sacrification and Specimen Harvesting

Twelve weeks after treatment, the rats were euthanized using CO_2, and their right Achilles tendons were resected and preserved in 10% formaldehyde solution (Fig. 1d).

Histopathological and Immunohistochemical Assessments

The preserved tendons were longitudinally embedded in paraffin blocks, and 5 µm thick slices were prepared for histochemical analysis. These slices were stained with hematoxylin & eosin, Alcian blue, and Masson trichrome. Histological assessment of the tendon samples was conducted using the modified Verhofstad scale, which evaluates tissue healing and inflammation across six parameters: 1) Fibrosis, 2) Polymorphonuclear leukocytes (PMNLs), 3) Edema, 4) Fibroblast abundance, 5) Vascularity, and 6) Collagen (Table 1) [15, 16].

The slices were further treated with CD45 and vimentin markers to assess collagen composition (Types I and III), inflammation, and fibroblast proliferation. Each sample was examined by two independent histologists, who were randomly assigned and worked in a double-blinded manner using Olympus™ BX51 light microscopy (Orinpasu Kabushiki-kaisha, Shinjuku, Tokyo, Japan) and photographed with an Olympus™ C5050 camera. The summary of the study protocol is presented in Figure 2.

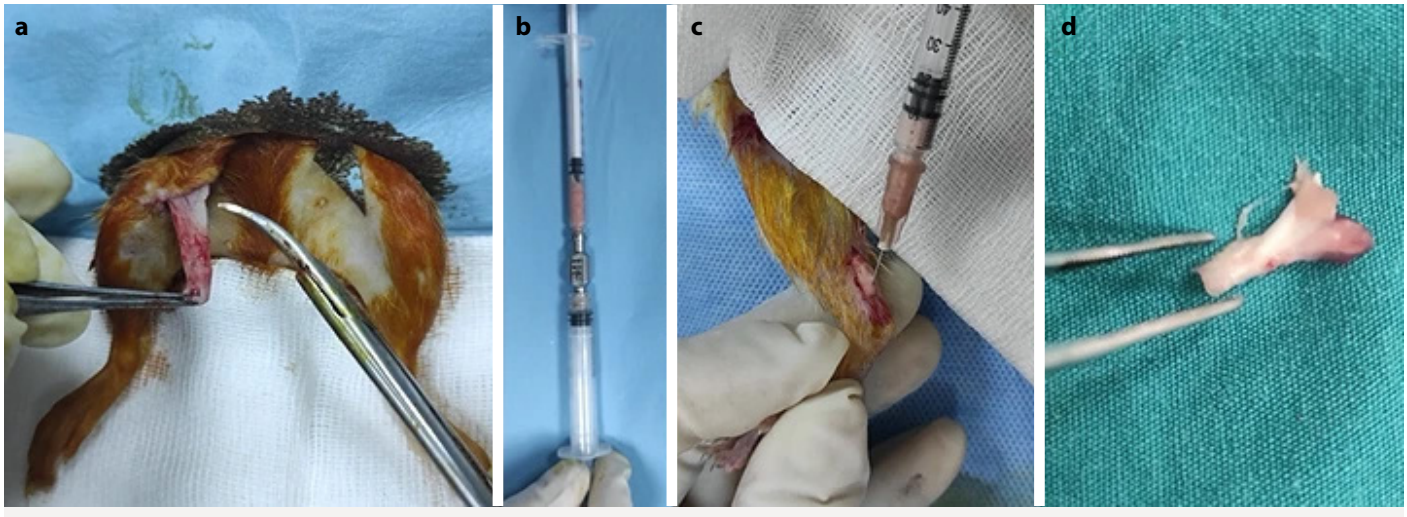

Figure 1. (a) Excision of Inguinal Fat Pads: Inguinal fat pads are excised from the rats as the source material for microfat and nanofat graft preparation. **(b)** Emulsification and Extraction Process: The excised fat tissue is passed through a Luer-lock cannula. Microfat grafts are prepared by passing the slashed tissue 20 times through a 2.4 mm cannula. For nanofat grafts, an additional 100 passages are made through a 1.2 mm cannula, followed by filtration through a 1 mm strainer to refine the grafts. **(c)** Nanofat Administration: The prepared nanofat graft is administered to the Achilles tendon via a posteromedial incision. **(d)** Resected Achilles Tendon: Post-treatment, the Achilles tendons are resected for histological and immunohistochemical analysis.

Table 1. Modified Verhofstad scale

Fibrosis	PMNs	Edema	Collagen density	Vascularity	Fibroblast proliferation
None	Normal	None	None	None	None
Superficial	Light	Light	Light	Light	Light
Pronounced	Pronounced	Pronounced	Pronounced	Pronounced	Pronounced
Massive	Massive	Dense	Dense	Dense	Dense

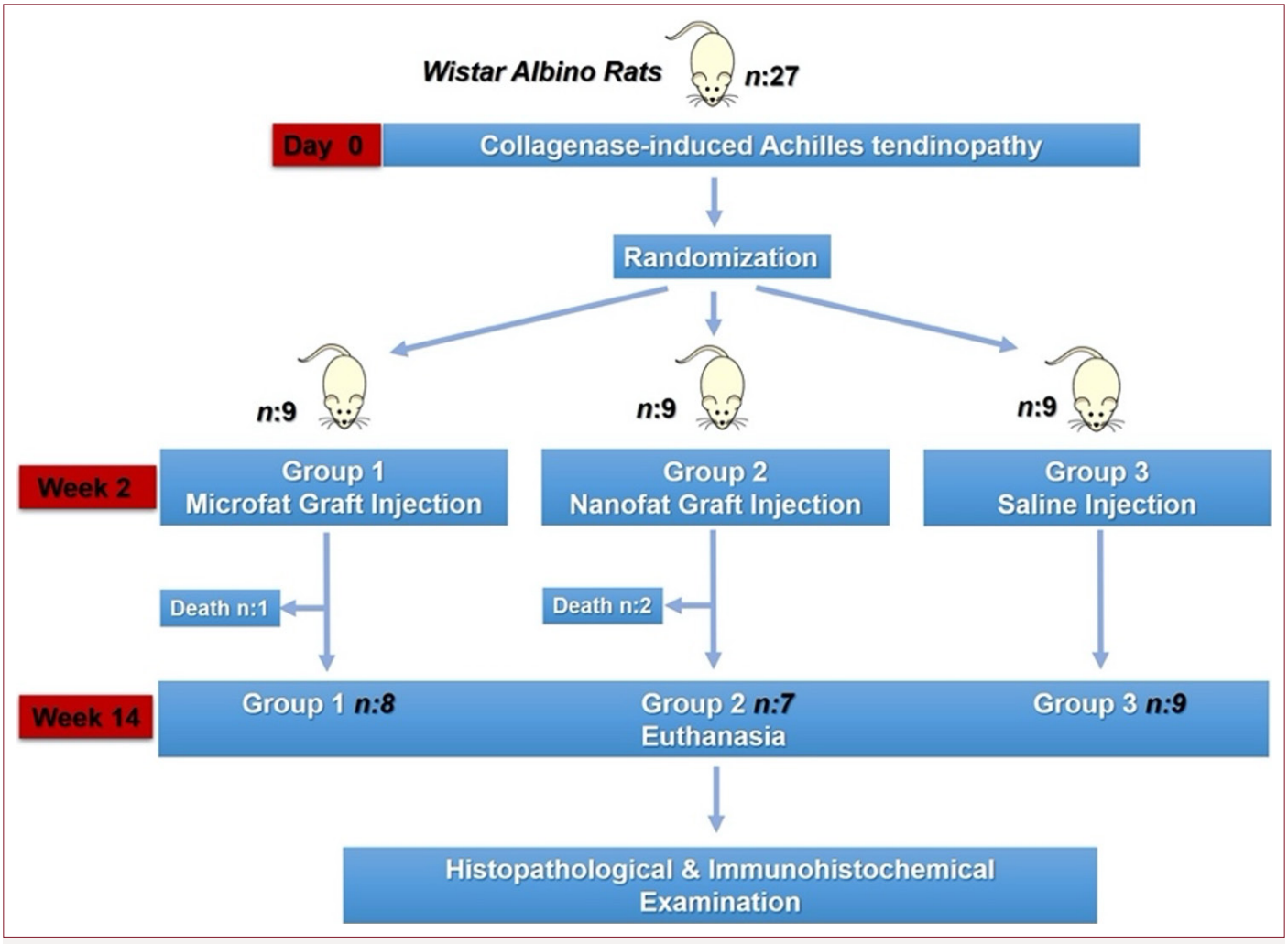

Figure 2. Flowchart of the study design.

Electron Microscopy

Scanning electron microscopy (SEM) was used to examine the ultrastructural composition of the fat grafts. Samples from both the nanofat and microfat preparations (one sample from each) were fixed with glutaraldehyde, dehydrated with alcohol and alcohol/hexamethyldisilazane, according to the Ege University Central Research Test and Analysis Laboratory Protocol. The samples were then coated with a 9 nm gold/palladium (Au/Pd) layer and examined using a Thermo Scientific/Apreo S™ scanning electron microscope.

Statistical Analysis

Statistical analyses were conducted using SPSS™ version 25 software (IBM Inc., Armonk, NY, USA). Due to the ordinal nature of the data and the inability to assume normal distribution,

non-parametric tests were used. Descriptive statistics, including median values and interquartile ranges (IQRs), were calculated for each group to summarize central tendencies and variability. For intergroup comparisons, the Kruskal-Wallis test was employed. This non-parametric method was selected as it is appropriate for comparing multiple independent groups when the data are not normally distributed. Post-hoc pairwise comparisons were conducted using the Mann-Whitney U test with Bonferroni correction to adjust for multiple comparisons. The corrected P-value threshold was determined by dividing the initial significance level (0.05) by the number of comparisons made.

RESULTS

Three rats, one from the microfat group and two from the nanofat group, died before the sacrifice. Additionally, two animals experienced bilateral wound dehiscence, and one had unilateral wound dehiscence at the inguinal incision site. A donor site hematoma was observed in one subject, which was promptly evacuated using a syringe. No other complications were encountered throughout the study.

Histopathological Findings

Qualitative Findings

The paratenon, a loose connective tissue surrounding the tendon proper, was identified in all specimens. Vascular elements, adipose cells, connective tissue cells, and the connective tissue matrix were observed within this paratenon. In the control group (Group 3), the blood vessels were notably dilated, and the paratenon area relative to the tendon was more prominent (Fig. 3).

A fibrotic region, likely corresponding to the injection site, was distinguishable in the control group, with signs of inflammation present within the collagen fibers. In the microfat group (Group 1), there was a slight reduction in edema within the collagen fibers, along with some polymorphonuclear leukocyte (PMNL) activity. In contrast, the nanofat group (Group 2) exhibited markedly reduced signs of inflammation, with minimal PMNL activity compared to the control and microfat groups.

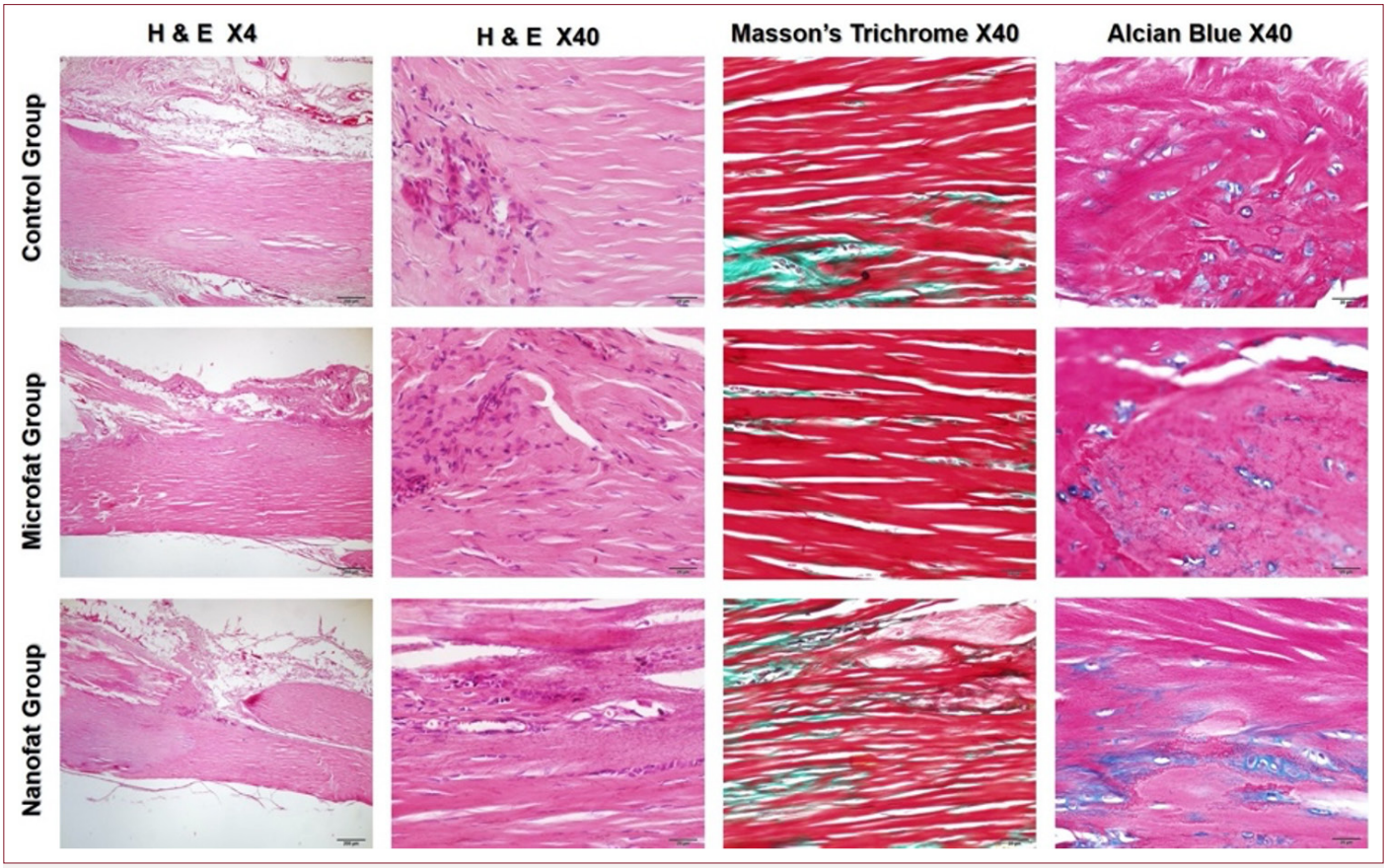

Figure 3. The appearance of the H&E, Masson trichrome and Alcian blue-stained preparations of the groups. The organization of the collagen fibers is visibly more uniform in the nanofat group, as well as the cellularity is markedly less predominant in the nanofat group compared to microfat and control groups.

Alcian blue staining of the specimens showed a tendency for fibroblast cells in all groups to be replaced by cells resembling chondrocytes, surrounded by a media similar to interterritorial matrix. In the control group, these cells were organized into large chondron-like structures, synthesizing a substantial amount of matrix. The organization was less pronounced in the microfat group, with the chondral cells appearing smaller. In the nanofat group, the synthesized matrix was scattered within the collagen fibers, and fewer chondral cells were observed (Fig. 3).

Quantitative Findings

The modified Verhofstad scores for the assessed specimens are provided in Table 2, with median values and interquartile ranges (IQR) shown in Table 3. Significant differences in the median Verhofstad scores were observed between the groups for all six parameters. Post-hoc analyses revealed significant differences between the microfat and nanofat groups in terms of PMNL infiltration (nanofat median: 1, IQR: 1-1; microfat median: 2, IQR: 2-3; p=0.015), tissue edema (nanofat median: 1, IQR: 1-1; microfat median: 2, IQR: 2-3; p=0.003), and collagen density (nanofat median: 1, IQR: 0-1; microfat median: 2, IQR: 2-3; p=0.003).

Immunohistochemical Findings

Type I collagen: In the control group, anti-type I collagen staining revealed low to medium immunoreactivity levels. In the microfat group, immunoreactivity was medium to high, while the nanofat group exhibited the highest levels (Fig. 4). Type III collagen: The highest level of immunoreactivity for

Table 2. The modified Verhofstad scores of the assessed specimens

	Fibrosis	PMNs infiltration	Edema	Collagen density	Vascularity	Fibroblast proliferation
Group 1 Control						
Sample 1	3	3	2	3	1	2
Sample 2	2	3	3	3	1	2
Sample 3	2	2	3	2	1	2
Sample 4	2	2	2	2	2	2
Sample 5	3	2	2	3	1	3
Sample 6	3	3	3	2	0	3
Sample 7	2	2	3	2	1	2
Sample 8	2	3	2	3	1	3
Sample 9	3	3	3	3	1	2
Group 2 Microfat						
Sample 1	2	2	1	2	2	2
Sample 2	3	3	2	2	2	2
Sample 3	2	3	3	1	3	1
Sample 4	2	2	2	2	2	2
Sample 5	1	1	3	3	3	2
Sample 6	1	1	2	3	2	2
Sample 7	2	2	3	1	2	1
Sample 8	1	2	2	2	1	1
Group 3 Nanofat						
Sample 1	1	1	1	1	2	1
Sample 2	1	0	1	0	3	1
Sample 3	2	0	2	1	3	1
Sample 4	2	2	1	1	2	1
Sample 5	1	1	1	0	2	2
Sample 6	0	1	0	1	3	1
Sample 7	1	1	1	0	3	2

Table 3. Median values and interquartile ranges for the groups

	Fibrosis	PMNs infiltration	Edema	Collagen density	Vascularity	Fibroblast proliferation
Control	2 (2-3)	3 (2-3)	3 (2-3)	3 (2-3)	1 (1-1)	2 (2-3)
Microfat	2 (1-2)	2 (2-3)	2 (2-3)	2 (2-3)	2 (2-3)	2 (1-2)
Nanofat	1 (1-2)	1 (1-1)	1 (1-1)	1 (0-1)	3 (2-3)	1 (1-2)
P_1	>0.016	>0.016	>0.016	>0.016	**0.003**	>0.016
P_2	**0.002**	**<0.001**	**0.008**	**<0.001**	**<0.001**	**<0.001**
P_3	>0.016	**0.015**	**0.003**	**0.003**	>0.016	>0.016

A Kruskal-Wallis test was used for multiple group comparisons, and Mann-Whitney U test was employed for pairwise post-hoc analyses with Bonferroni correction. P_1 represents the comparisons between the P_1 control group and the microfat group, P_2 denotes the comparisons between the P_2 control group and the nanofat group, and P_3 illustrates the comparisons between the microfat and nanofat groups.

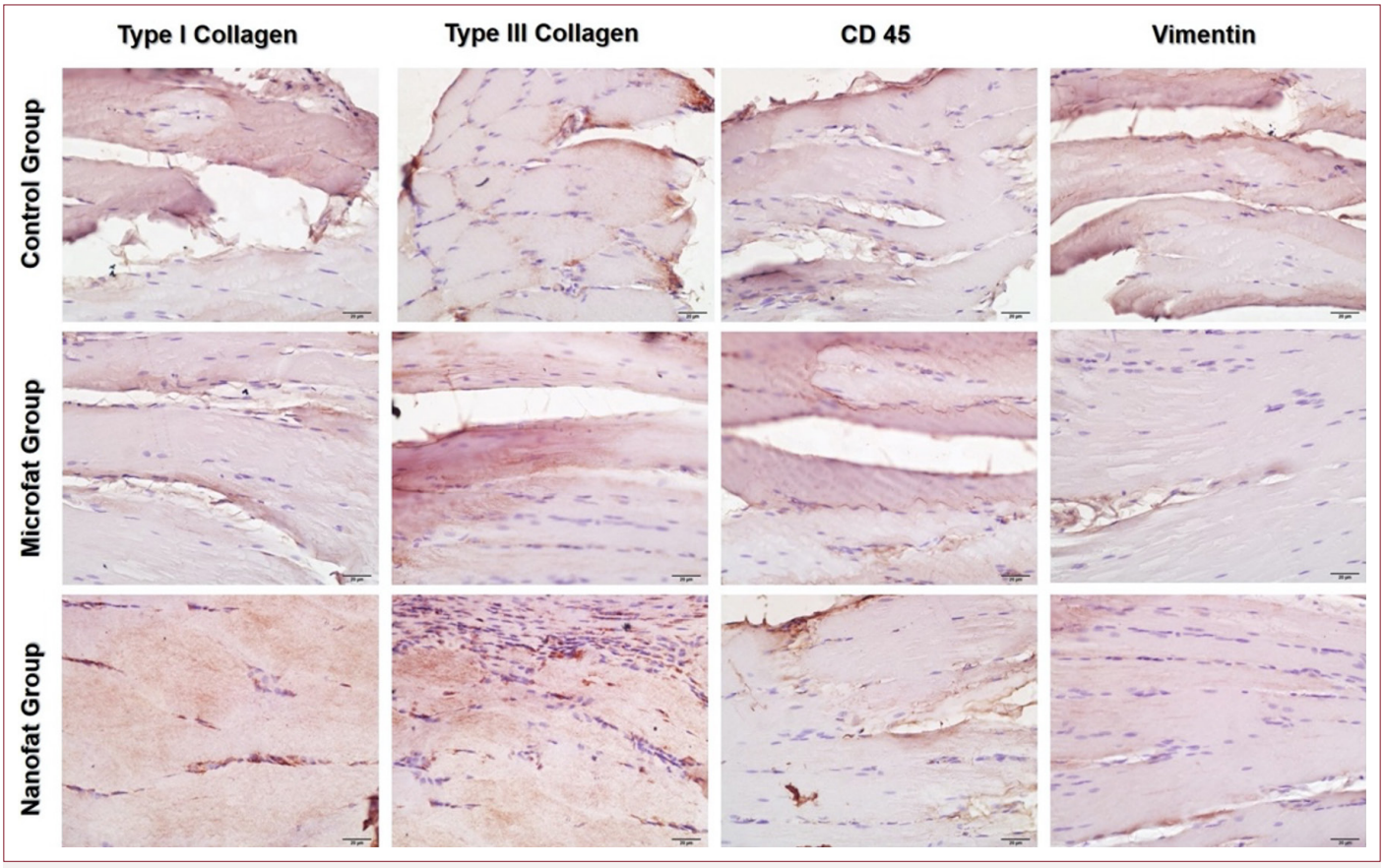

Figure 4. The appearance of the preparations stained with anti-type I collagen, anti-type III collagen, anti-CD45 and anti-vimentin primary antibodies of the experimental groups.

type III collagen was observed in the nanofat group, with the lowest levels found in the control group (Fig. 4). CD45 antibodies: CD45 immunoreactivity corresponded with the H&E staining. The control group showed the most diffuse staining, while the microfat group demonstrated focal dye retention. In contrast, immunoreactivity was scarce in the nanofat group (Fig. 4). Vimentin: The mesodermal cell marker vimentin was most prominent in the control group, while it was found at modest levels in both the microfat and nanofat groups (Fig. 4).

Electron Microscopic Findings

In the electron microscopy examination, intact adipocyte globules with diameters up to 50 micrometers, along with the matrix scaffold, were observed in the microfat sample. In contrast, the nanofat sample showed the presence of extracellular matrix, stromal vascular fraction (SVF), and extracellular vesicles with diameters around 2 micrometers (2000 nanometers) or smaller (Fig. 5).

DISCUSSION

In this study, we demonstrated that nanofat grafts significantly improved healing and reduced inflammation compared to microfat grafts and controls in a collagenase-induced rat model of chronic Achilles tendinopathy. Nanofat, with its higher concentration of mesenchymal stem cells (MSCs) and growth factors from the stromal vascular fraction, resulted in lower levels of polymorphonuclear leukocyte (PMNL) infiltration, reduced tissue edema, and increased collagen density, indicating a more robust regenerative response. These findings support the hypothesis that nanofat, with its superior regenerative and anti-inflammatory properties, may be a more effective treatment for chronic tendinopathy than microfat or standard interventions. Additionally, the higher immunoreactivity for type I and III collagen observed in the nanofat group further underscores its potential to enhance tendon healing at the molecular level.

The use of fat grafts as both structural and biological fillers, along with the discovery of their regenerative properties, marked a significant advancement in regenerative medicine. This breakthrough was largely driven by the identification of adipose-derived stem cells (ADSCs) in 2001, which opened new avenues for fat graft applications beyond traditional plastic surgery [10, 17-19]. Today, adipose-derived stem cells are used in various fields, including cardiology for cardiomyoblast formation, neurology for neural cell development, and orthopedics for treating conditions like arthritis [18, 19].

In particular, the regenerative potential of microfat grafts, which contain pluripotent stem cells and stromal vascular cells (SVC) alongside mature adipocytes, has been widely recognized. Unlike traditional fat grafts, which are primarily used for volumizing, microfat grafts emphasize their regenerative capacity, making them suitable for a range of treatments, particularly in the facial region [20]. Tonnard et al. [21] introduced further refinement of this technique by mechanically emulsifying fat grafts, resulting in nanofat, a preparation that lacks mature adipocytes but retains endothelial cells, macrophages, mast cells, stromal vascular fraction (SVF), and adipose-derived stem cells (ASCs). This preparation is highly regenerative and can be injected through fine needles, serving as a potent regenerative tool rather than a volumizing agent [22].

Our study's findings align with this regenerative potential, as the nanofat group demonstrated significantly improved histopathological tendon healing compared to both the control and microfat groups. Furthermore, the reduced presence of hyaline cartilage degeneration around the Achilles tendon—an avascular region—was most prominent in the nanofat group, likely due to the enhanced vascularity induced



Figure 5. Scanning Electron Microscopic view of the; **(a)** microfat (to scale, magnification is 2500x), **(b)** nanofat samples (magnification is 10 000x). In microfat samples, the cellular and extracellular structures are preserved, while in the nanofat group, no cellular component can be identified (the diameter of the cell-like spheres are smaller than the smallest resident cell in the mesenchyme).

by mesenchymal stem cells (MSCs) and growth factors from the stromal vascular fraction. The increased dominance of type I collagen in the nanofat group, a key factor in tendon mechanical strength, further supports the regenerative advantages of nanofat in tendon healing.

Electron microscopy findings in our study were consistent with existing literature [23]. While microfat preparations contained scattered mature adipocytes and fat globules, nanofat preparations were predominantly composed of extracellular matrix, mesenchymal stem cells, and smaller extracellular vesicles such as exosomes [24]. Unlike previous applications of structural and cultured fat grafts in treating foot-related issues, nanofat grafts function primarily as biological regenerative agents rather than providing structural support [25].

Chronic tendinopathies, which affect a significant portion of the physically active population, including athletes and the elderly, can severely limit daily activities and performance. As societies increasingly embrace physical activity to combat health issues like cardiovascular disease and diabetes, finding effective treatments for tendinopathies is crucial. Traditional methods, such as steroid and non-steroidal anti-inflammatory drugs, provide short-term relief but are ineffective in addressing the chronic imbalance between collagen production and degradation, which is at the core of the condition. Newer therapies have yielded inconsistent or unproven results, including low-dose laser treatments, iontophoresis, and extracorporeal shock waves. Surgical options, while available, are often a last resort due to mixed outcomes. Given these challenges, our study's findings suggest that nanofat grafts may offer a promising, minimally invasive alternative for treating chronic tendinopathies by promoting tissue regeneration and reducing inflammation. This approach could potentially improve the quality of life for individuals struggling with chronic tendon conditions, enabling them to maintain an active lifestyle without the limitations imposed by traditional therapies.

Several limitations of this study should be acknowledged. First, using an animal model, specifically rats, poses inherent challenges in directly extrapolating the findings to human clinical scenarios despite the similarities in tendon healing mechanisms between mammals. Although animal models are widely used in preclinical studies to explore biological processes and treatment efficacy, physiological and anatomical differences may affect the translatability of the results to human tendinopathies. Second, the study did not include biomechanical testing to assess tendon endurance and functional recovery post-treatment. While the histopathological findings provide valuable insights into the healing process, the lack of biomechanical data limits the ability to evaluate the functional improvements in tendon strength and durability, which are critical for clinical applications. Third, the exact genetic and immunological composition of the nanofat and microfat grafts used in this study was not fully documented. Although both graft types were prepared using established techniques, the absence of detailed analysis on the specific cellular and molecular components limits the ability to understand the regenerative mechanisms involved fully. A more comprehensive characterization of the grafts, including the specific concentrations of growth factors, cytokines, and stromal vascular fraction cells, would enhance the understanding of their therapeutic potential. Finally, the study duration of 12 weeks, while sufficient to observe significant histological changes, may not capture the long-term effects and sustainability of the treatments. A longer follow-up period would be necessary to evaluate the potential for lasting tendon regeneration and functional recovery.

CONCLUSION

In conclusion, this study demonstrated that nanofat grafts, rich in mesenchymal stem cells, exosomes, and growth factors, significantly improved tendon healing and reduced inflammation compared to microfat grafts and control treatments in a collagenase-induced rat model of chronic Achilles tendinopathy. Nanofat applications resulted in superior histopathological outcomes, including reduced fibrosis, edema, and polymorphonuclear leukocyte infiltration, as well as increased collagen density and vascularity, which likely contributed to better tendon regeneration. The presence of a higher proportion of type I collagen in the nanofat group further supports its potential for enhancing tendon mechanical strength. While these findings highlight nanofat's regenerative capabilities, the study's limitations, including the use of an animal model and the absence of biomechanical testing, must be considered when extrapolating these results to clinical practice. Future research should focus on biomechanical assessments and long-term follow-up in human studies to better understand the clinical applicability of nanofat grafts in treating chronic tendinopathies.

DECLARATIONS

Ethics Committee Approval: The Ege University Animal Experiments Local Ethics Committee granted approval for this study (date: 28.05.2020, number: 2020-055).

Author Contributions: Idea/Concept – AB, YU, EKB; Design – AB, YU, EKB; Control/Supervision – AB, EKB; Data Collection and/or Processing – AB, KK, OFD, CT, YU, EKB; Analysis and/or Interpretation – AB, YU, EKB; Literature review – AB, KK, OFD, EKB; Writing – AB, KK, CT, YU, EKB; Critical Review – AB, YU, EKB; References and fundings – AB, YU, EKB; Materials – AB, KK, OFD, CT, YU, EKB.

Data Avaliability Statement: The data that support the findings of this study are available from the corresponding author upon reasonable request.

Conflict of Interest: The authors declared no conflict of interest.

Informed Consent: Not applicable.

Use of AI for Writing Assistance: The authors declared that they had not used any type of generative artificial intelligence for the writing of this manuscript, nor for the creation of images, graphics, tables, or their corresponding captions.

Financial Disclosure: The authors declare that they have no relevant or material financial interests that relate to the research described in this paper.

Funding Disclosure: This study was funded by Ege University Office of Scientific Research Projects in the field of medicine. The project number is 21885. Follow-up number is TGA-2020-21885.

Peer-review: Externally peer-reviewed.

ABBREVIATIONS

MSC - Mesenchymal Stem Cell

PBS - Phosphate-Buffered Saline

PMNL - Polymorphonuclear Leukocyte

PRP - Platelet-Rich Plasma

BMSC - Bone Marrow Stem Cell

ASC - Adipose-Derived Stem Cell

SEM - Scanning Electron Microscopy

SVF - Stromal Vascular Fraction

NSAID - Nonsteroidal Anti-Inflammatory Drug

ARRIVE - Animal Research: Reporting of In Vivo Experiments

H&E - Hematoxylin & Eosin

TGF-ß - Transforming Growth Factor-Beta

bFGF - Basic Fibroblast Growth Factor

BMP-12 - Bone Morphogenetic Protein 12

REFERENCES

1. Andres BM, Murrell GAC. Treatment of tendinopathy: What works, what does not, and what is on the horizon. Clin Orthop Relat Res 2008;466:1539–54. [CrossRef]
2. Mead MP, Gumucio JP, Awan TM, Mendias CL, Sugg KB. Pathogenesis and management of tendinopathies in sports medicine. Transl Sports Med 2018;1:5–13. [CrossRef]
3. Woodley BL, Newsham-West RJ, Baxter GD. Chronic tendinopathy: Effectiveness of eccentric exercise. Br J Sports Med 2007;41:188–98. [CrossRef]
4. Adebayo A, Nash P, Hazleman B. A prospective double blind dummy placebo controlled study comparing triamcinolone hexacetonide injection with oral diclofenac 50 mg TDS in patients with rotator cuff tendinitis. J Rheumatol 1990;17:1207–10.
5. Jomaa G, Kwan CK, Fu SC, Ling SK, Chan KM, Yung PS, et al. A systematic review of inflammatory cells and markers in human tendinopathy. BMC Musculoskelet Disord 2020;21:78. [CrossRef]
6. Paoloni JA, Murrell GAC. Three-year followup study of topical glyceryl trinitrate treatment of chronic noninsertional achilles tendinopathy. Foot Ankle Int 2007;28:1064–8. [CrossRef]
7. Ho JO, Sawadkar P, Mudera V. A review on the use of cell therapy in the treatment of tendon disease and injuries. J Tissue Eng 2014:5:2041731414549678. [CrossRef]
8. Mishra A, Pavelko T. Treatment of chronic elbow tendinosis with buffered platelet-rich plasma. Am J Sports Med 2006;34:1774–8. [CrossRef]
9. Trebinjac S, Gharairi M. Mesenchymal stem cells for treatment of tendon and ligament ınjuries-clinical evidence. Med Arch 2020;74:387–90. [CrossRef]
10. Zuk PA, Zhu M, Mizuno H, Huang J, Futrell JW, Katz AJ, et al. Multilineage cells from human adipose tissue: Implications for cell-based therapies. Tissue Eng 2001;7:211–28. [CrossRef]
11. Feng J, Zhang Y, Zhu Z, Gu C, Waqas A, Chen L. Emerging exosomes and exosomal MiRNAs in spinal cord injury. Front Cell Dev Biol 2021;9:703989. [CrossRef]
12. Kamat P, Frueh FS, McLuckie M, Sanchez-Macedo N, Wolint P, Lindenblatt N, et al. Adipose tissue and the vascularization of biomaterials: Stem cells, microvascular fragments and nanofat—a review. Cytotherapy 2020;22:400–11. [CrossRef]
13. Percie du Sert N, Hurst V, Ahluwalia A, Alam S, Avey MT, Baker M, et al. The ARRIVE guidelines 2.0: Updated guidelines for reporting animal research. PLoS Biol 2020;18:e3000410. [CrossRef]
14. Orfei CP, Lovati AB, Viganò M, Stanco D, Bottagisio M, Di Giancamillo A, et al. Dose-related and time-dependent development of collagenase-ınduced tendinopathy in rats. PLoS One 2016;11:e0161590. [CrossRef]
15. Verhofstad MHJ, Lange WP, Van Der Laak JAWM, Verhofstad AAJ, Hendriks T. Microscopic analysis of anastomotic healing in the intestine of normal and diabetic rats. Dis Colon Rectum 2001;44:423–31. [CrossRef]
16. Yeğin ME, Bilkay U, Tiftikçioğlu YÖ, Uyanıkgil Y, Çavuşoğlu T, Ercan G et al. Altering effects of caffeic acid phenethyl ester (CAPE) and ischemia/reperfusion injury: an experimental study in a rat TRAM flap model. Eur J Plast Surg 2020;5:527–34. [CrossRef]

17. Coleman SR. Structural fat grafts: The ideal filler? Clin Plast Surg 2001;28:111–9. [CrossRef]
18. Oh JS, Park IS, Kim KN, Yoon DH, Kim SH, Ha Y. Transplantation of an adipose stem cell cluster in a spinal cord injury. Neuroreport 2012;23:277–82. [CrossRef]
19. Zhou B, Yuan J, Zhou Y, Ghawji M Jr, Deng YP, Lee AJ, et al. Administering human adipose-derived mesenchymal stem cells to prevent and treat experimental arthritis. Clin Immunol 2011;141:328–37. [CrossRef]
20. Nguyen A, Guo J, Banyard DA, Fadavi D, Toranto JD, Wirth GA, et al. Stromal vascular fraction: A regenerative reality? Part 1: Current concepts and review of the literature. J Plast Reconstr Aesthet Surg 2016;69:170–9. [CrossRef]
21. Tonnard P, Verpaele A, Peeters G, Hamdi M, Cornelissen M, Declercq H. Nanofat grafting: Basic research and clinical applications. Plast Reconstr Surg 2013;132:1017–26. [CrossRef]
22. Sesé B, Sanmartín JM, Ortega B, Matas-Palau A, Llull R. Nanofat cell aggregates: A nearly constitutive stromal cell ınoculum for regenerative site-specific therapies. Plast Reconstr Surg 2019;144:1079–88. [CrossRef]
23. Yang Z, Jin S, He Y, Zhang X, Han X, Li F. Comparison of microfat, nanofat, and extracellular matrix/stromal vascular fraction gel for skin rejuvenation: Basic research and clinical applications. Aesthet Surg J 2021;41:NP1557–70. [CrossRef]
24. Ding P, Lu E, Li G, Sun Y, Yang W, Zhao Z. Research progress on preparation, mechanism, and clinical application of nanofat. J Burn Care Res 2022;43:1140–4. [CrossRef]
25. Molligan J, Mitchell R, Bhasin P, Lakhani A, Schon L, Zhang Z. Implantation of autologous adipose tissue-derived mesenchymal stem cells in foot fat pad in rats. Foot Ankle Int 2015;36:1344–51. [CrossRef]

STArt Sports Traumatology & Arthroscopy
TUSYAD
DOI: 10.14744/start.2024.43955
Sports Traumatol Arthrosc 2024;1(1):14-23

Original Article

Efficacy of Retrograde Bone Grafting for Cystic Osteochondral Lesions of the Tibial Plafond: A Retrospective Study

Mehmet Baris Ertan, Huseyin Selcuk, Hakan Cetin, Firat Dogruoz, Omer Faruk Egerci

Department of Orthopedics and Traumatology, University of Health Sciences, Antalya Training and Research Hospital, Antalya, Türkiye

ABSTRACT

Objective: This study evaluated the clinical and radiological outcomes of patients with cystic osteochondral lesions of the tibial plafond (OLTP) treated with retrograde cancellous bone grafting.

Materials and Methods: A retrospective review was conducted on patients who underwent surgery for OLTP at our institution from 2012 to 2023. Eleven patients (7 females, 4 males; mean age 41.9 years) were included. Preoperative, intraoperative, and postoperative data were analyzed, including radiological assessments using direct radiography, CT, and MRI. The surgical technique involved retrograde cancellous bone grafting, with postoperative rehabilitation and follow-up evaluations using the AOFAS score.

Results: The mean clinical follow-up period was 75.7 (median: 79, range: 12-137) months. The mean preoperative AOFAS score improved significantly from 56.0 to 89.3 (p=0.003). Radiological follow-up showed cyst consolidation in seven patients, while four experienced recurrences (36.3%). Recurrence was associated with persistent communication between the cyst cavity and the joint space.

Conclusion: Retrograde cancellous bone grafting significantly improves clinical outcomes in patients with cystic osteochondral lesions of the tibial plafond, as demonstrated by a marked increase in postoperative AOFAS scores compared to preoperative values. However, a high recurrence rate of 36.3% highlights the need for advancements in surgical techniques to achieve complete healing. Successful outcomes hinge on the effective obliteration of the communication between the cyst and the ankle joint space.

Keywords: Ankle, Bone cysts, Osteochondral lesions, Retrograde grafting, Tibial plafond

Cite this article as:
Ertan MB, Selcuk H, Cetin H, Dogruoz F, Egerci OF, et al. Efficacy of Retrograde Bone Grafting for Cystic Osteochondral Lesions of the Tibial Plafond: A Retrospective Study. Sports Traumatol Arthrosc 2024;1(1):14-23.

Address for correspondence:
Mehmet Baris Ertan. Department of Orthopedics and Traumatology, University of Health Sciences, Antalya Training and Research Hospital, Antalya, Türkiye
E-mail:
mehmetbarisertan@gmail.com

Submitted: 16.08.2024
Revised: 24.10.2024
Accepted: 29.10.2024
Available Online: 28.11.2024

Sports Traumatology & Arthroscopy – Available online at www.stajournal.com

This work is licensed under a Creative Commons Attribution-NonCommercial 4.0 International License.

INTRODUCTION

Osteochondral lesions of the tibial plafond (OLTP) are less common compared to those of the talus and can occur as isolated lesions or coexist with osteochondral lesions of the talus (OLT). The incidence of OLTP in the general population remains poorly defined. Mologne and Ferkel [1] reported OLTP in 2.6% of 880 patients undergoing ankle arthroscopy, while Elias et al. [2] found a 15.2% incidence in 250 ankle MRI examinations. Advances in diagnostic imaging and ankle arthroscopy

have improved the recognition and understanding of OLTP, revealing that they are not as rare as previously thought and can coexist with talar osteochondral lesions as kissing lesions.

OLT lesions are classified into various grades, with cyst formation classified as Grade 5 according to the Hepple classification [3]. For high-grade cystic lesions, it is recommended to address both the cystic component and the cartilage lesion simultaneously. Common treatments include antegrade or retrograde curettage and grafting of the cyst or filling with an osteochondral plug. While there are numerous studies on OLT treatment, limited studies exist on OLTP, and no consensus has been reached on treatment principles. The literature also presents confusion regarding the definition of high-grade lesions with cyst formation, with some authors treating these as intraosseous ganglion cysts due to their gelatinous fluid content and identical histopathological characteristics.

This retrospective study aims to assess the outcomes of patients treated for cystic osteochondral lesions of the tibial plafond (OLTP) with retrograde cancellous bone grafting. The procedure is hypothesized to be an effective treatment for OLTP, leading to significant improvements in clinical outcomes and functional scores. A comprehensive analysis of preoperative, intraoperative, and postoperative data, including radiologic assessments, was conducted to evaluate the efficacy of this approach. The study seeks to contribute to the ongoing discussion on optimal management strategies for OLTP.

MATERIALS AND METHODS

Patients and Study Design

A retrospective review was conducted using the digital patient database at the authors' institution between 2012 and 2023 to identify patients who underwent surgery for OLTP. The medical records, follow-up notes, and operative notes were extracted, and the demographic and clinical characteristics of the patients were compiled. All preoperative, postoperative, and follow-up radiologic examinations of the patients were obtained using PACS, including direct radiography, CT, and MRI. Eleven patients were identified over an 11-year period. Patients with a less than one-year radiologic follow-up period, those who declined to participate in the study, and those with incomplete medical information were excluded. The study was conducted following the principles of the Declaration of Helsinki and was approved by the institutional ethics committee (date and issue: date: 13.06.2024, number: 9/17). Informed consent was obtained from all patients.

Surgical Technique and Postoperative Rehabilitation

All procedures were performed under spinal anesthesia with the patient in a supine position, utilizing a thigh tourniquet for control. For medially located lesions, a 3-4 cm longitudinal incision was made over the medial malleolus. A cortical window was created to access the cyst, which was evacuated, and the sclerotic bone exposed by curettage. The cyst was then filled using cancellous bone autograft harvested from the anterior iliac crest and packed with an impaction technique. In one case, a synthetic bone graft was used due to patient preference. To prevent medial malleolus fracture and provide stability, a single titanium screw was placed. For centrally located lesions, an anterior approach was employed, involving the creation of an anterior tibial cortical window. In one instance, an anterior tibial osteotomy was performed for better access to the cyst, and screws were used to fix the osteotomy after grafting. In patients with both tibial and talar lesions (kissing lesions), a biplanar chevron medial malleolar osteotomy was performed. The tibial cyst was addressed through the osteotomy, while the talar lesion was treated with mosaicplasty, using an osteochondral plug harvested from the lateral trochlear region of the knee. After grafting and mosaicplasty, the medial malleolus was fixed with compression screws.

Postoperatively, all patients were immobilized in a below-knee splint for three weeks to ensure soft tissue healing. Active and passive ankle exercises were initiated after this period, with gradual weight-bearing as tolerated. Full weight-bearing and return to daily activities were allowed following radiological confirmation of healing, typically 6-8 weeks after surgery.

Radiological Evaluations

Before surgery, all patients underwent anteroposterior and lateral ankle radiography, ankle computerized tomography (CT), and magnetic resonance imaging (MRI). The cyst volume was measured using CT, and the location of the lesion was evaluated using the nine-zone anatomic grid scheme described by Elias et al. [2]. Direct radiographs were used for postoperative follow-up, but CT or MRI was also ordered to detect recurrence in suspicious cases.

Clinical Evaluations

All patients were invited to the hospital for the final follow-up. However, only nine responded to the invitation and completed their clinical and radiologic follow-up. Three patients who lived out of town were interviewed over the phone, and their final radiologic follow-ups were obtained digitally from other hospital archives. Ankle function was evaluated using the AOFAS score, and all complications during the follow-up period were recorded.

Statistical Analysis

Continuous variables were presented as mean, median, standard deviation, and range, while categorical data were presented as frequency and percentage. The Related Samples Wilcoxon Signed Rank Test was used to compare the preoperative and postoperative functional scores with a significance level set at $p<0.05$.

RESULTS

Patient Demographics and Clinical Characteristics

There were 11 patients (7 females, 4 males) with a mean age of 41.9±12.5 years (median: 39, range: 23-60). Four patients had lesions in their right ankle, while seven had lesions in their left ankle. Detailed demographic and clinical characteristics are presented in Table 1.

Preoperative Radiological Findings

Direct radiography revealed the cyst as an oval osteolytic lesion surrounded by a thin sclerotic margin in all patients. The cyst was typically located between the medial malleolus and tibial plafond in 9 out of 11 patients and in the midline just above the subchondral bone of the tibial plafond in two patients. In one case, the cyst caused thinning of the medial malleolus cortex (Fig. 1). On CT examination, the findings were consistent with the direct radiographic observations, showing the lesion as cystic and surrounded by a sclerotic rim. Eight cysts were uniocular, while three were multiocular. The mean cyst volume was 555.8±324 mm^3 (median: 523 mm^3, range: 129-1080 mm^3). The cyst cavity communicated with the ankle joint through a small hole in the subchondral bone (Fig. 2). MRI examination further characterized the cysts. T2-weighted and Proton Density Weighted (PDW) sequences highlighted the fluid within the cysts and adjacent bone marrow edema as hyperintense areas. T1-weighted images revealed hypointense cystic areas with potential cartilage and subchondral bone interface irregularities (Fig. 3).

Clinical Outcomes

All patients experienced an uneventful postoperative period with no wound healing problems or infection. However, one patient (Case #4) developed reflex sympathetic dystrophy in the 6th week postoperatively, which was successfully treated with physical therapy. The mean clinical follow-up period was 75.7±44.9 months (median: 79, range: 12-137). The mean preoperative AOFAS score was 56.0±13.7 (median: 52, range: 29-75) and significantly improved to 89.3±8.6 (median: 90, range: 73-100) ($p=0.003$) (Table 2). Screw removal was necessary in three cases (Cases #6, #7, and #8) due to implant-related discomfort.

Radiological Outcomes

The average radiologic follow-up period was 55.1±39.3 months (median: 47, range: 12-130). Recurrence of the cyst was detected in 4 patients (36.3%) at the last follow-

Table 1. Demographic and clinical characteristics of patients

Case No.	Age	Sex	Side	Zone	Volume (mm^3)	Uni/Multiocular	Surgical Approach	Graft Choice	Screw Fix.	F/U (Months)	
										Rad.	Cl.
1	36	F	R	4	584	Uniocular	Medial	Autograft	Yes	12	12
2	35	F	L	4	422	Multiocular	Medial	Autograft	Yes	79	79
3	42	F	L	5	129	Uniocular	Anterior	Autograft	No	32	32
4	39	F	L	4	1080	Uniocular	MMO	Allograft	Yes	74	86
5	25	M	R	2	240	Uniocular	MMO	Autograft	Yes	47	70
6	23	F	L	4	628	Uniocular	Medial	Autograft	Yes	63	120
7	51	M	L	4	1026	Multiocular	Medial	Autograft	Yes	130	137
8	59	M	R	4	523	Uniocular	Medial	Autograft	Yes	26	130
9	38	F	L	4	311	Uniocular	Medial	Allograft	No	108	108
10	53	M	L	5	890	Multiocular	Anterior	Autograft	Yes	15	38
11	60	F	R	4	281	Uniocular	Medial	Autograft	Yes	21	21

Cl: Clinical; F/U: Follow up; F: Female; Fix: Fixation; L: Left; M: Male; R: Right; Rad: Radiological.

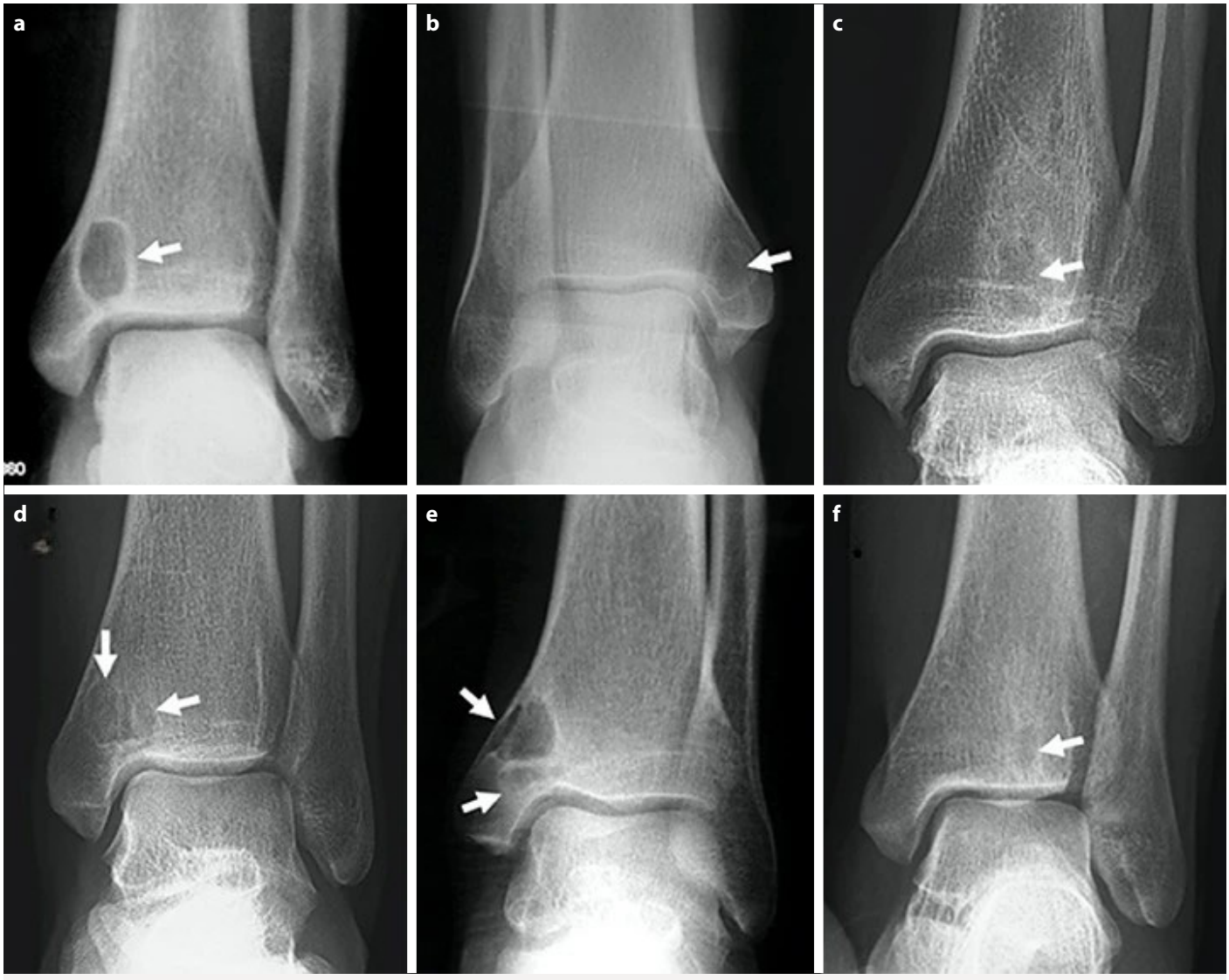

Figure 1. Direct anteroposterior ankle radiographs of six different patients showing the osteochondral lesions of the tibial plafond **(a-f)**. In each case there was an oval osteolytic lesion in the bone. The lesion was characterized by a clear, defined boundary and is surrounded by a thin sclerotic margin, indicative of a cystic structure (white arrows).

up, while the cyst was completely consolidated in seven patients (Fig. 4). Among the two patients with recurrence, a CT scan was performed at the last follow-up, revealing that the communication between the cyst cavity and joint space persisted (Fig. 5).

DISCUSSION

This study analyzed the radiologic and clinical results of retrograde grafting of large cystic OLTP. Despite a high rate of radiological recurrence (36.3%), the improvement in postoperative AOFAS scores from a mean of 56.0 to 89.3 signifies a substantial clinical benefit of this treatment modality. The reduction in cyst volume and pressure as well as the decrease in reactional bone marrow edema surrounding the cyst may have contributed to the improvement in functional scores, particularly the pain. Recurrence of the cyst might be attributed to the inadequate healing of the existing communication between the cyst cavity and the adjacent joint space. Consequently, a pivotal aspect of the surgical intervention involves the deliberate obliteration and subsequent healing of this connection.

One of the most notable radiologic findings in this study is the evident communication between the cyst cavity and the joint space. The use of 3D CT examination facilitated the identification of the presence and location of the

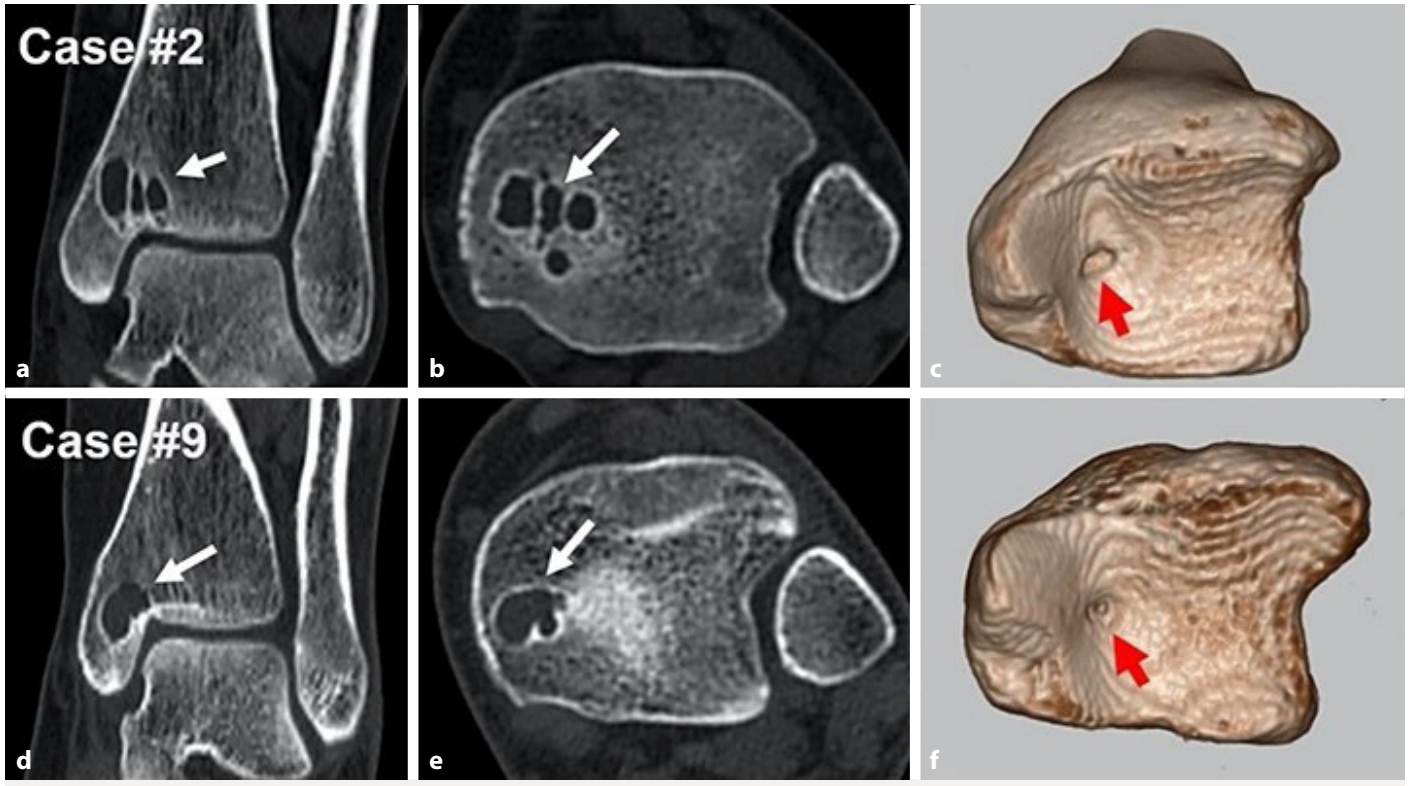

Figure 2. CT images of cystic lesions in two different cases. Case #2: **(a)** Sagittal view showing a multiocular cyst (arrow) with a sclerotic rim. **(b)** Axial view of the same cyst, highlighting multiple compartments (arrow). **(c)** 3D reconstruction demonstrating a small hole (red arrow) in the subchondral bone, allowing communication with the ankle joint. Case #9: **(d)** Sagittal view displaying a uniocular cyst (arrow) with a sclerotic margin. **(e)** Axial view of the cyst, confirming its single compartment (arrow). **(f)** 3D reconstruction revealing a small hole (red arrow) in the subchondral bone, similar to Case #2.

communication. This finding also clarifies the pathomechanism of these cysts and has been cited in previous studies. Loesch et al. [4] reported a case in which a peri-articular bony cyst failed to consolidate after curettage and bone grafting due to communication with the ankle joint, allowing synovial fluid to seep into the cyst. They proposed that the presence of synovial fluid, which contains anti-angiogenic factors that inhibit bone healing, is a crucial factor in the failure of consolidation and recurrence of the cyst. Similarly, Coulier et al. [5] described a case with fistulous gas communication between the ankle joint and the ganglion cyst of the medial malleolus. Finally, Büchler et al. [6] discussed the treatment of five intraosseous ganglion cysts in the distal tibia using an arthroscopically assisted technique. Arthroscopic examination showed that all the treated intraosseous lesions were connected to the joint despite various locations in the distal tibia. The consistent finding of a small area of soft and fissured cartilage with an underlying defect of the subchondral bone, which provides direct access to the subchondral cyst, supports the theory that these cysts originate from the joint. In summary, cyst recurrence is primarily caused by communication between the cyst cavity and the joint space, which allows synovial fluid to enter the cystic structure. This infiltration is facilitated by a 'check-valve' mechanism, where the fluid is pumped into the cyst during joint movements but prevented from flowing back into the joint. This mechanism increases internal pressure and promotes cyst enlargement. The seepage of synovial fluid promotes the growth of the cyst and delivers anti-angiogenic factors that impede healing. To prevent recurrence, it is crucial to identify and obliterate the joint connection, allowing for the generation of scar tissue that can seal the pathway. This enables proper healing and prevents the fluid dynamics that underpin cyst persistence or recurrence. Likewise, in two cases of recurrence that underwent postoperative CT examination, subchondral communication remained unhealed in our series. Our findings align with previous studies, such as Loesch et al. [4], who similarly identified the persistent communication between the cyst and joint space as a major contributor to recurrence. Their observation that synovial fluid seeping into the cyst prevents healing resonates with our results,

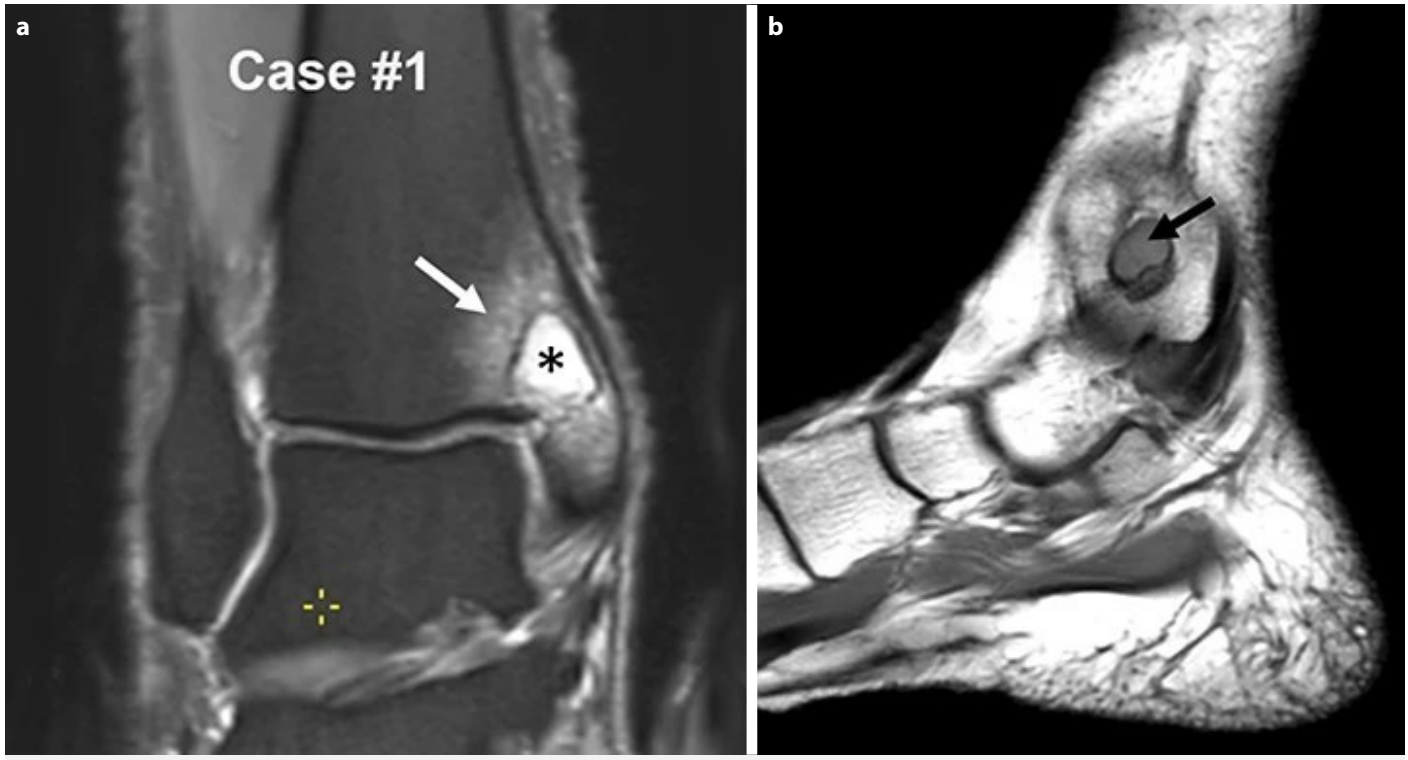

Figure 3. MRI examination highlighting cystic lesions and adjacent bone marrow edema. Case #1: **(a)** Coronal T2-weighted image showing a hyperintense cystic lesion (asterix) with adjacent bone marrow edema (white arrow). **(b)** Sagittal T1 weighted image displaying the hyperintense fluid within the cyst (black arrow), indicating the cystic nature of the lesion and associated bone changes.

Table 2. Clinical outcomes and recurrence

Case #	Preoperative AOFAS score	Final Follow-Up AOFAS score	Recurrence
1	52	90	No
2	48	90	Yes
3	49	82	No
4	29	88	No
5	45	100	No
6	68	100	No
7	58	90	Yes
8	75	100	No
9	70	80	Yes
10	70	90	No
11	52	73	Yes

AOFAS: American Orthopedic Foot and Ankle Society.

highlighting the importance of achieving a complete closure of this pathway during surgery. Despite this, our study shows that even when radiological recurrence occurs, patients can still experience significant functional improvements, suggesting that retrograde cancellous bone grafting offers durable symptom relief and improved quality of life.

The literature on the treatment of osteochondral lesions of the tibial plafond presents a range of approaches, each with its own merits and limitations. In our extensive literature review, only 20 previous studies and case reports could be identified (Table 3) [1,4,6–23]. Compared to previous studies on osteochondral lesions of the tibial plafond (OLTP), our study provides valuable insights into retrograde cancellous bone grafting as a treatment option.

In terms of surgical techniques, various approaches have been explored in the literature. Arthroscopic techniques, such as those employed by Hayashi and Tanaka [20], provide a less invasive option with faster recovery times and reduced postoperative complications. However, these are often associated with fibrocartilage formation, which may not offer the same long-term durability as native hyaline cartilage. Similarly, Desai et al. [15] and Cuttica et al. [12] found that while arthroscopic debridement and microfracture led to early functional improvements, recurrence rates remained

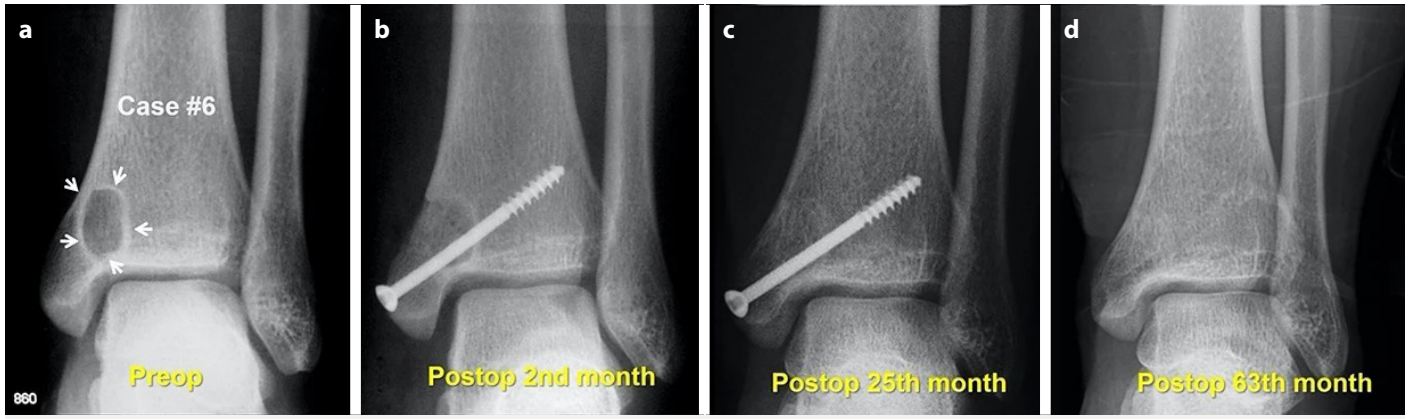

Figure 4. Radiographs showing the consolidation of a cyst in a patient over time. Case #6: **(a)** Preoperative anteroposterior radiograph indicating the cystic lesion (arrows). **(b)** Anteroposterior radiograph at 2 months postoperative, showing the initial healing. **(c)** Anteroposterior radiograph at 25 months postoperative, with further consolidation of the cyst. **(d)** Anteroposterior radiograph at 63 months postoperative, demonstrating complete consolidation of the cyst and successful long-term healing.

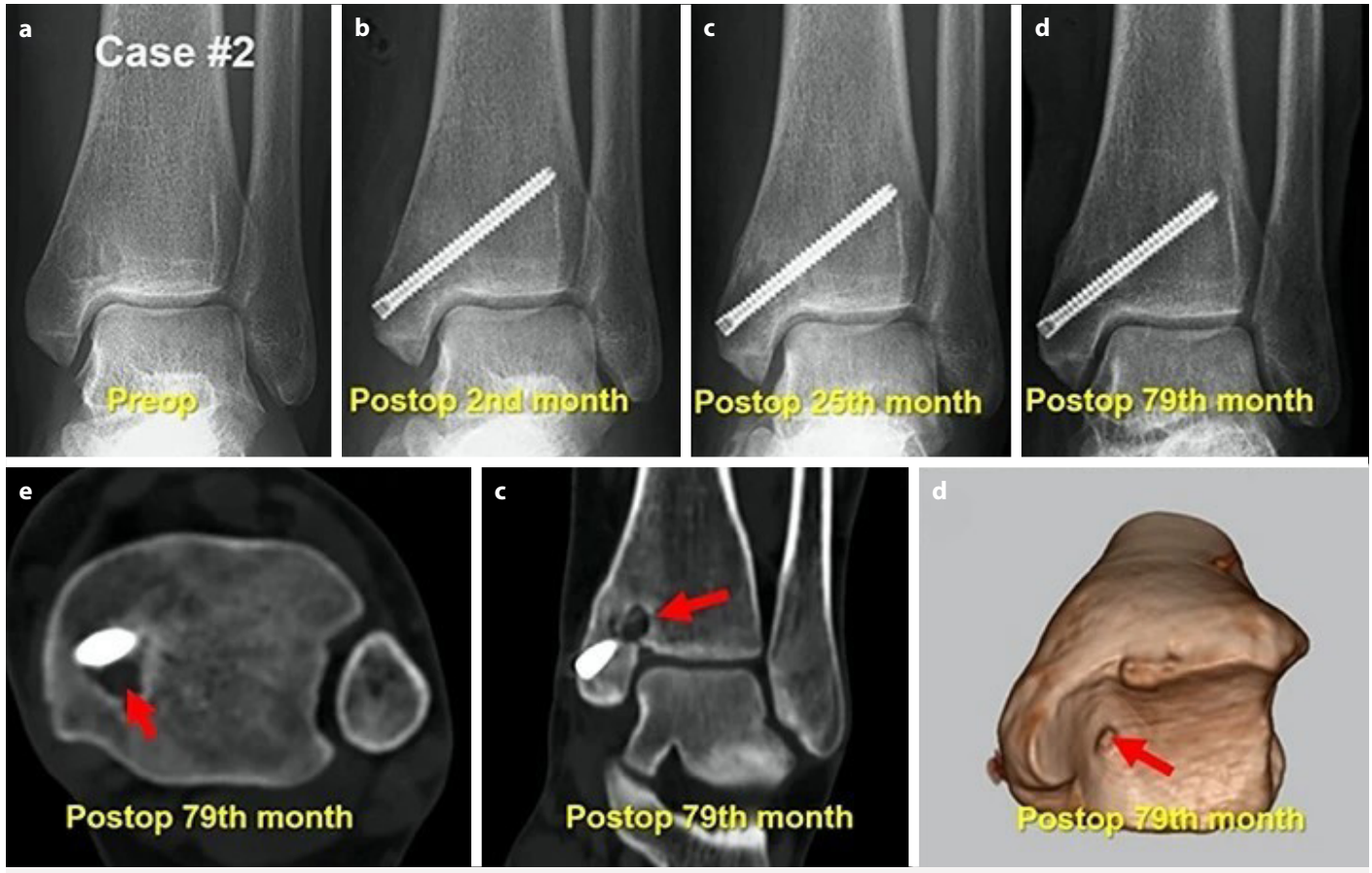

Figure 5. Radiographs and CT scans demonstrating the recurrence during the follow-up. Case #2: **(a)** Preoperative anteroposterior radiograph showing the cystic lesion. **(b)** Anteroposterior radiograph at the 2nd postoperative month. **(c)** Anteroposterior radiograph at 25th postoperative month. **(d)** Anteroposterior radiograph at 79 postoperative months. **(e)** Axial CT scan at 79 months postoperative showing recurrence of the lesion (red arrow). **(f)** Coronal CT scan at 79 months postoperative highlighting the same recurrent cyst (red arrow). **(g)** 3D reconstruction at 79 months postoperative illustrating the persistent communication (red arrow).

Table 3. Previously reported studies and case reports on OLTP

Author	Year	Patients	Cystic cases	Treatment	Functional Outcome	Recurrence
Andrews et al. [7]	1991	1	1	BMS	Two years postoperatively he is doing well with no residual symptoms.	-
Ferkel et al. [8]	1999	3	3	Bone graft and curettage	Satisfactory long-term result	-
Sopov et al. [9]	2001	1	1	Conservative	Good	NR
Mologne and Ferkel [1]	2007	17	2	BMS	AOFAS score from 52 to 87	1
Buchler et al. [6]	2009	5	5	BMS and bone graft	AOFAS scores from 73 to 94	-
Pearce et al. [10]	2009	1	1	BMS and synthetic graft.	AOFAS scores from 66 to 90	-
Aurich et al. [11]	2011	3	NR	MACI	AOFAS from 58.6 to 80.4	-
Cuttica et al. [12]	2012	13	3	BMS	AOFAS from 35.2 to 50.4	3 patients
Ross et al. [13]	2014	31	NR	BMS	FAOS pain score from 50.5 to 74.2	NR
Loesch et al. [4]	2015	1	1	Arthroscopy-assisted medial malleolar osteotomy curettage and grafting	Very good	-
Sedeek et al. [14]	2015	1	1	Bone graft and curettage	no pain or limitation of movement at the last visit (2 years postoperatively)	-
Desai [15]	2016	1	0	BMS and Allograft Cartilage Matrix	Very good	-
Okamura et al. [16]	2017	2	1	Retrograde OATS	Very good	-
Baldassarri et al. [17]	2018	27	2	BMDCT bone marrow-derived cell transplantation	AOFAS score from 52.4 to 80.6	two had incomplete lesion repair
Mohapatra et al. [18]	2018	1	1	Bone cement and curettage	No signs of recurrence and is completely relieved of pain and limping.	-
Lee et al. [19]	2019	16	NR	BMS	All functional scores showed significant differences clinically and statistically at the final follow-up.	-
Hayashi et al. [20]	2019	1	NR	Arthroscopic Antegrade Cancellous Bone Autotransplantation	Satisfactory clinical results	-
Nery et al. [21]	2021	1	1	Retrograde arthroscopic-guided OATS	Excellent clinical and radiological midterm results	-
Mei et al. [22]	2022	18	18	Curettage and Bone graft	AOFAS ascore from 78.2±13.7 to 97.3±4.5	-
Wei et al. [23]	2023	40	0	BMS	AOFAS score increased from 57.5to 88	-

BMS: Bone marrow stimulation (microfracture); NR: Not reported; AOFAS: American Orthopaedic Foot and Ankle Society; MACI: Matrix-Associated Chondrocyte Implantation; FAOS: Foot and Ankle Outcome Score; OATS: Osteochondral Autograft Transfer System; BMDCT: Bone Marrow-Derived Cell Transplantation.

high, and fibrocartilage formation was a common issue. This is consistent with our finding while retrograde cancellous bone grafting is more invasive, it provides superior long-term functional outcomes for large cystic lesions, even when radiological recurrence is present.

Studies utilizing synthetic osteochondral grafts, such as those by Pearce et al. [10], also report favorable clinical outcomes but still face challenges with recurrence, mirroring our results. Okamura et al. [16], who used retrograde osteochondral autograft transfer, similarly observed that while clinical improvements were evident, recurrence persisted in some cases. These findings highlight that the type of graft used—whether autograft, allograft, or synthetic—may have little impact on recurrence if the connection between the cyst and the joint space is not properly closed.

The biomechanical complexity of the tibial plafond, compared to osteochondral lesions of the talus (OLT), further complicates treatment. Büchler et al. [6] and Mologne et al. [1] both observed that OLTP tends to have higher recurrence rates than OLT, likely due to the unique loading patterns and cartilage characteristics of the tibial plafond. This difference emphasizes the need for tailored surgical strategies to address the biomechanical demands of the tibial plafond, rather than directly applying techniques developed for OLT. In addition to biomechanical factors, patient-specific considerations such as lesion size, location, and the presence of kissing lesions also play a role in determining the most appropriate treatment modality. Studies like those by Ross et al. [13] and Andrews et al. [7] highlight the importance of customizing surgical interventions based on these factors to optimize outcomes. This is particularly relevant in our series, where larger, more complex cystic le aggressive surgical approach to ensure functional improvement.

Strengths and Limitations

One significant limitation of the present study is its retrospective nature and the constrained sample size. However, only 11 cases were admitted over a decade at a high-volume university hospital, highlighting the rarity of these lesions and the challenges in accruing a larger cohort. Additionally, the absence of a control group further limits the ability to compare outcomes with alternative treatment modalities. It is important to recognize that the variability in surgical techniques, including the choice between allograft and autograft or the decision to use additional screw fixation, introduces confounding factors that could influence the results. Despite these limitations, the study has some strengths, such as the long duration of follow-up and the use of advanced imaging techniques both before and after the operation, which enhance the reliability of the findings.

CONCLUSION

This study demonstrates that retrograde cancellous bone grafting is an effective treatment for large cystic osteochondral lesions of the tibial plafond, leading to significant improvements in clinical outcomes, as reflected by AOFAS scores. Despite a recurrence rate of 36.3%, which is likely due to the persistent communication between the cyst cavity and the joint space, patients experienced notable functional recovery. This suggests that clinical improvement can still be achieved even when radiological evidence indicates cyst persistence or recurrence. The results highlight the need for advanced surgical techniques to fully close this communication and reduce recurrence rates. Future studies should focus on comparing various surgical approaches, including minimally invasive techniques, to optimize long-term outcomes for these challenging lesions.

DECLARATIONS

Ethics Committee Approval: The Antalya Training and Research Hospital Clinical Research Ethics Committee granted approval for this study (date: 13.06.2024, number: 9/17).

Author Contributions: Idea/Concept – MBE, HS, HC, FD, OFE; Design – MBE, HS, HC, FD, OFE; Control/Supervision – OFE; Data Collection and/or Processing – HS, HC, OFE; Analysis and/or Interpretation – HC, HS, MBE, MY; Literature review – MBE, FD, OFE; Writing – MBE, FD, OFE; Critical Review – OFE, HC, HS; References and fundings – MBE, FD, OFE

Data Avaliability Statement: The data that support the findings of this study are available from the corresponding author upon reasonable request.

Conflict of Interest: The authors had no conflict of interest to declare.

Informed Consent: Informed consent were obtained from the participants.

Use of AI for Writing Assistance: In the writing of this manuscript, no Large Language Model (LLM) was used in the study design, writing, literature review, or statistical analyses.

Financial Disclosure: The authors declare that they have no relevant or material financial interests that relate to the research described in this paper.

Funding Disclosure: No funding was received for this study

Peer-review: Externally peer-reviewed.

ABBREVIATIONS

AOFAS - American Orthopaedic Foot and Ankle Society

CT - Computerized Tomography

MMO - Medial Malleolar Osteotomy

MRI - Magnetic Resonance Imaging

OLT - Osteochondral lesions of the talus

OLTP - Osteochondral lesions of the tibial plafond

PDW - Proton Density Weighted

REFERENCES

1. Mologne TS, Ferkel RD. Arthroscopic treatment of osteochondral lesions of the distal tibia. Foot Ankle Int 2007;28:865–72. [CrossRef]
2. Elias I, Raikin SM, Schweitzer ME, Besser MP, Morrison WB, Zoga AC. Osteochondral lesions of the distal tibial plafond: localization and morphologic characteristics with an anatomical grid. Foot Ankle Int 2009;30:524–9. [CrossRef]
3. Hepple S, Winson IG, Glew D. Osteochondral lesions of the talus: A revised classification. Foot Ankle Int 1999;20:789–93. [CrossRef]
4. Loesch EC, Bamne AB, Kwon JY. Failure of consolidation of a peri-articular distal tibial bone cyst post curettage due to communication with the ankle joint. Orthop J Harvard Med Sch 2015;16:112–5.
5. Coulier B, Devyver B, Hamels J. Imaging demonstration of fistulous gas communication between joint and ganglion of medial malleolus. Skeletal Radiol 2002;31:57–60. [CrossRef]
6. Büchler L, Hosalkar H, Weber M. Arthroscopically assisted removal of intraosseous ganglion cysts of the distal tibia. Clin Orthop Relat Res 2009;467:2925–31. [CrossRef]
7. Andrews JR, Tedder JL, Godbout BP. Simple bone cyst of the distal tibia: A case for ankle arthroscopy. Arthroscopy 1991;7:381–4. [CrossRef]
8. Ferkel RD, Field J, Scherer WP, Bernstein ML, Kasimian D, Van Nuys M, et al. Intraosseous ganglion cysts of the ankle: A report of three cases with long-term follow-up. Foot Ankle Int 1999;20:384–8. [CrossRef]
9. Sopov V, Liberson A, Groshar D. Bilateral distal tibial osteochondral lesion: A case report. Foot Ankle Int 2001;22:901–4. [CrossRef]
10. Pearce CJ, Lutz MJ, Mitchell A, Calder JDF. Treatment of a distal tibial osteochondral lesion with a synthetic osteochondral plug: A case report. Foot Ankle Int 2009;30:900–3. [CrossRef]
11. Aurich M, Bedi HS, Smith PJ, Rolauffs B, Mückley T, Clayton J, et al. Arthroscopic treatment of osteochondral lesions of the ankle with matrix-associated chondrocyte implantation: Early clinical and magnetic resonance imaging results. Am J Sports Med 2011;39:311–9. [CrossRef]
12. Cuttica DJ, Smith WB, Hyer CF, Philbin TM, Berlet GC. Arthroscopic treatment of osteochondral lesions of the tibial plafond. Foot Ankle Int 2012;33:662–8. [CrossRef]
13. Ross KA, Hannon CP, Deyer TW, Smyth NA, Hogan MC, Do HT, et al. Functional and MRI outcomes after arthroscopic microfracture for treatment of osteochondral lesions of the distal tibial plafond. J Bone Joint Surg Am 2014;96:1708–15. [CrossRef]
14. Sedeek SM, Choudry Q, Garg S. Intraosseous ganglion of the distal tibia: Clinical, radiological, and operative management. Case Rep Orthop 2015;2015:1–4. [CrossRef]
15. Desai S. Surgical treatment of a tibial osteochondral defect with debridement, marrow stimulation, and micronized allograft cartilage matrix: Report of an all-arthroscopic technique. J Foot Ankle Surg 2016;55:279–82. [CrossRef]
16. Okamura K, Sugimoto K, Isomoto S, Samoto N, Yoneda A, Tsukada N, et al. Osteochondral lesion of the tibial plafond treated with a retrograde osteochondral autograft: A report of two cases. Asia Pac J Sports Med Arthrosc Rehabil Technol 2017;8:8–12. [CrossRef]
17. Baldassarri M, Perazzo L, Ricciarelli M, Natali S, Vannini F, Buda R. Regenerative treatment of osteochondral lesions of distal tibial plafond. Eur J Orthop Surg Traumatol 2018;28:1199–207. [CrossRef]
18. Mohapatra A, Patel V, Choudhury P, Phalak M. Intraosseous ganglion cyst of the distal tibia: A rare entity in a rarer location. BMJ Case Rep 2018;2018:bcr2018224395. [CrossRef]
19. Lee W, Tran S, Cooper MT, Park JS, Perumal V. Clinical outcomes of osteochondral lesions of the tibial plafond following arthroscopic microfracture. Foot Ankle Int 2019;40:1018–24. [CrossRef]
20. Hayashi K, Tanaka Y. Arthroscopic antegrade cancellous bone autotransplantation for osteochondral lesions of the tibial plafond. Arthrosc Tech 2019;8:e875–81. [CrossRef]
21. Nery C, Prado M, Brauer G, Lemos AV. Retrograde autologous osteochondral transplantation in treating osteochondral lesion of distal tibial plafond: A case report and technical tips. Foot Ankle Int 2021;42:1081–92. [CrossRef]
22. Mei Z, Lei W, Huang D, Ma W, Pan G, Ni L, et al. Diagnosis and treatment of ıntraosseous ganglion in the ankle region. Z Orthop Unfall 2022;162:143–8. [CrossRef]
23. Wei Y, Yun X, Song J, Qi W, Li J, Liu Y, et al. Clinical outcomes after arthroscopic microfracture treatment of coexisting talar and tibial osteochondral lesions. Orthop J Sports Med 2023;11:23259671231172977. [CrossRef]

STArt
Sports Traumatology & Arthroscopy
TUSYAD
DOI: 10.14744/start.2024.80679
Sports Traumatol Arthrosc 2024;1(1):24-32

Original Article

Comparison of Two Different Intraarticular Hyaluronic Acid Injection Regimens in Knee Osteoarthritis: A Randomized Clinical Trial

Ali Bozdemir,[1] Melih Unal,[2] Mehmet Baris Ertan,[3] Omer Faruk Egerci[2]

[1]Department of Orthopedics and Traumatology, Karacabey State Hospital, Bursa, Türkiye
[2]Department of Orthopedics and Traumatology, University of Health Sciences, Antalya Training and Research Hospital, Antalya, Türkiye
[3]Department of Orthopedics and Traumatology, Medikum Private Hospital, Antalya, Türkiye

ABSTRACT

Objective: The purpose of this randomized clinical trial was to compare the pain and knee function between a single-dose (Sodium hyaluronate 3%, 2 ml, 60 mg) versus two-weekly (Sodium hyaluronate 1.6%, 2 ml, 32 mg) intraarticular hyaluronic acid (HA) injections in mild to moderate symptomatic knee osteoarthritis (OA).

Materials and Methods: Sixty patients with clinically and radiographically confirmed knee OA were randomly divided into two groups for two HA injection regimens. The first group received a single-dose 60 mg HA, while the second group received two-weekly 32 mg HA injections. Pain and knee function were evaluated with the Visual Analogue Scale (VAS) and Western Ontario and McMaster University Osteoarthritis Index (WOMAC) before injection and first, third, and sixth months after injections.

Results: There was no significant difference in baseline characteristics, including age, sex, body mass index, and OA grade, between the two groups (p:n.s. for all variables). Our analysis showed that total WOMAC and VAS mean scores improved compared to the baseline measurements ($p<0.001$ for both scores). However, regarding the minimal important change (MIC) values for both VAS and WOMAC, there was no significant difference between the groups at the final follow-up ($p=0.217$ and $p=0.500$, respectively). An adequate pain reduction could not be achieved in more than half of the patients (56.6%), and almost half (45%) did not have a clinically significant increase in knee function at the final follow-up according to MIC values. No major complications were seen.

Conclusion: This study failed to show a significant benefit or clinically important change after viscosupplementation regardless of the tested dosing regimens.

Keywords: Knee, osteoarthritis, hyaluronic acid, viscosupplementation, WOMAC, Intra-articular injections

Cite this article as:
Bozdemir A, Unal M, Ertan MB, Egerci OF, et al. Comparison of Two Different Intraarticular Hyaluronic Acid Injection Regimens in Knee Osteoarthritis: A Randomized Clinical Trial. Sports Traumatol Arthrosc 2024;1(1):24-32.

Address for correspondence:
Melih Unal.
Department of Orthopedics and Traumatology, University of Health Sciences, Antalya Training and Research Hospital, Antalya, Türkiye
E-mail:
meliih_unal@hotmail.com

Submitted: 22.10.2024
Revised: 05.11.2024
Accepted: 05.11.2024
Available Online: 28.11.2024

Sports Traumatology & Arthroscopy – Available online at www.stajournal.com

This work is licensed under a Creative Commons Attribution-NonCommercial 4.0 International License.

INTRODUCTION

Primary knee osteoarthritis (OA) is a common disease affecting a significant number of subjects older than 50. In a recent meta-analysis on population-based observational studies, the pooled global incidence of knee OA was 203/10,000 person-years (95% CI, 106–331) in subjects older than 20 years [1]. It is characterized by loss of cartilage, derangements of the subchondral bone and synovial tissue, inflammation, osteophyte formation, and degeneration of all structures forming the joint. Patients with knee OA experience pain, loss of knee motion, deformity, and, consequently, loss of quality of life [2]. During the early stages of the disease, conservative treatment is usually chosen. Several methods might be used for symptomatic relief of symptoms, including weight loss, using walking aids, structured land-based exercise programs and physiotherapy, topical or oral anti-inflammatory drugs, oral supplements such as glucosamine, and a variety of intraarticular injections, including hyaluronic acid (HA), platelet-rich plasma (PRP), and corticosteroids [3,4].

HA, a major component of the cartilage extracellular matrix, is produced and secreted by chondrocytes and synoviocytes. Injections of HA, also known as viscosupplementation, have been used as a treatment for knee OA since getting clearance in Japan and Italy in 1987-1988. The idea behind this treatment is to supplement the natural HA in the joint, re-establish the synovial fluid's characteristics, which can become depleted in OA, and improve the lubrication and cushioning of the joint to reduce pain and improve function [5-7]. Currently, several HA products are available on the market with different molecular weights, concentrations, volumes, and a number of injections recommended.

Several previous studies have shown the safety and efficacy of HA injections for knee OA [8-11]. However, controversy still exists on the best injection regimen. A wide range of administrations, at different molecular weights and structures, quantities, and at different injection intervals (a single injection to 5 weekly injections), have been reported up-to-date [12-14]. Some studies have suggested that a single high-dose HA injection may be as effective as multiple lower-dose injections, while others have found that multiple injections provide better results [15-24]. On the other hand, a single high-dose HA injection might reduce patient visits, the number of invasive procedures, and the overall cost. The hypothesis for this study was that a single 60 mg injection of intra-articular HA would be as safe and effective as two weekly 32 mg injections in reducing pain and improving knee function in patients with mild to moderate knee OA. The purpose of this randomized clinical trial was to compare the pain and knee function following either single-dose (Sodium hyaluronate 3%, 2 ml, 60 mg) or two weekly (Sodium hyaluronate 1.6%, 2 ml, 32 mg) intraarticular HA injections.

MATERIALS AND METHODS

Patients and Study Design

This study was a prospective randomized controlled clinical trial (RCT) that included patients with mild to moderate knee OA who were elected for intra-articular HA injection. The study was conducted in a tertiary university hospital between 2020 and 2021. Patients who received any previous intraarticular injection, who underwent previous knee surgery, who have a history of inflammatory diseases such as rheumatoid arthritis, posttraumatic knee OA, neuromuscular disorders, history of psychiatric illness, body mass index (BMI) greater than 40 kg/m^2, and patients who denied participation were excluded from the study. Knee OA criteria set by the American College of Rheumatology were used for the diagnosis [24]. Patients with mild to moderate knee OA (grade II and III), according to Kellgren–Lawrence radiographic grading scale, were assessed for eligibility.

The study was conducted according to the ethical standards in the 1964 Declaration of Helsinki and its later amendments, and the institutional review board approved the study protocol (IRB approval date/issue: 07.11.2019, 24/2). Informed consent was obtained from the participants. The study followed the guidelines for RCTs outlined in the "CONSORT statement." [25].

Sample Size Calculation and Randomization

The sample size was computed using the G*Power program (Ver. 3.1.9.6, Dusseldorf, Germany). The power of the study was predicted to be 90% when 28 patients in each group (total: 56 with equal allocation ratio) were included at the level of two-tailed alpha (0.05) and effect size 0.99 based on the study by Zoboli et al. [16]. Considering the possibility of drop-out from the study after enrollment, 60 patients were included. The opaque sealed envelope method was used to achieve allocation concealment for randomization. Sixty envelopes were prepared and mixed. On the day of the HA injection, one envelope was chosen and removed from the pool. Both the physician and the patient were not blinded to the intervention.

The content of the Injections

Two different doses of HA were used for this study. HA injection was provided in a sterile 2 ml glass syringe. In the single injection group, (Sodium hyaluronate 3%, 2 ml, 60 mg) was used. In the two-weekly injection group, (Sodium hyaluronate 1.6%, 2 ml, 32 mg) was used. The product was a biologically fermented HA with a molecular weight of 2.9-3.8 mDa for 32 mg injections and 1.8-2.5 mDa for 60 mg injections. Table 1 summarizes the content of the HA preparations.

Table 1. The content of the HA injections used in the study

Composition	Single injection	Two-weekly injections
Volume	2.0 ml	2.0 ml
Sodium Hyaluronate	60 mg	32 mg
Sodium Chloride	17 mg	17 mg
Disodium Hydrogen Phosphate	1.126 mg	1.126 mg
Sodium Dihydrogen Phosphate	0.090 mg	0.090 mg
Molecular weight	1.8-2.5 mDa	2.9-3.8 mDa
Osmolality	270 - 400 mOsm/kg	270 - 400 mOsm/kg
pH	6.8 - 7.6	6.8 - 7.6
Zero Shear Viscosity	350.000 - 650.000 mPa.s	350.000 - 550.000 mPa.s
Water for injection	q.s	q.s

q.s. : quantum sufficit; mDa: million Dalton.

Radiological Evaluation

All patients had standing posteroanterior (PA) and lateral knee radiographs with the X-ray beam centered on the knee joint line. Kellgren–Lawrence radiographic grading scale was used to classify the radiological grade of knee OA [26]. Radiological ratings were performed on digital radiographs stored in picture archiving and communication systems (PACS) by two independent observers once using the software program Sectra IDS7 (Ver. 18.2., Sectra AB, Linköping, Sweden) on the digital workstation. K-statistics were used to establish a relative level of agreement between the observers. The agreement was graded as slight (κ=0–0.2), fair (κ=0.21–0.40), moderate (κ=0.41–0.60), substantial (κ=0.61–0.80), and almost perfect (κ=0.81–1) according to Landis and Koch [27]. Interobserver reliability was found to be substantial (κ=0.645). There were three patients on whom agreement could not be reached. The two observers mutually decided on these patients for the final analysis.

Injection Technique

The superolateral approach was chosen for the intraarticular knee injection. The patients were placed in the supine position with the knee in extension. After sterile knee preparation, the superolateral border of the patella was palpated, and the patella was gently tilted medially to ease access to the joint. A 21 G needle with a 10 mL syringe was inserted underneath the patella to gain access to the joint space. Synovial fluid was aspirated, if present, as much as possible; the needle was left inside the joint without changing the position, and the syringe was replaced with HA containing syringe. The injection was completed within ~10 seconds, and the needle puncture was closed with a sterile adhesive strap.

Follow-up and Data Collection

The pain was assessed using the Visual Analogue Scale (VAS). A 100mm ruler with a visual depiction of pain levels (smiling face to frowning face) was used. Patients were told their previous pain scores at each assessment. Knee function was evaluated using Western Ontario and McMaster University Osteoarthritis Index (WOMAC) [28]. Both evaluations were performed before the injection and at first, third, and sixth-month follow-ups. All complications and adverse effects were monitored during the study period. At least 3-points reduction in VAS and 17-points reduction in WOMAC were accepted as a clinically meaningful improvement considering the minimal important change (MIC) reported in previous studies [29,30].

Statistical Analysis

Statistical analysis was performed using SPSS Statistics Base v.23 for Windows. Descriptive statistics were reported as mean and standard deviation, frequency distribution, median, minimum and maximum values. The Shapiro-Wilk test was employed to examine the normality assumption. Normally distributed variables were analyzed with the student t-test, and non-normally distributed variables were analyzed with the Mann-Whitney-U-test. Categorical variables were compared with the Chi-square test. Repeated measures within the same group were compared with repeated measures of ANOVA. A value of $p<0.05$ was accepted as statistically significant.

RESULTS

The trial enrolled 60 patients who met the inclusion criteria, 30 of whom were equally assigned to each group. Figure 1 illustrates the progression of patients during the trial. None of the patients

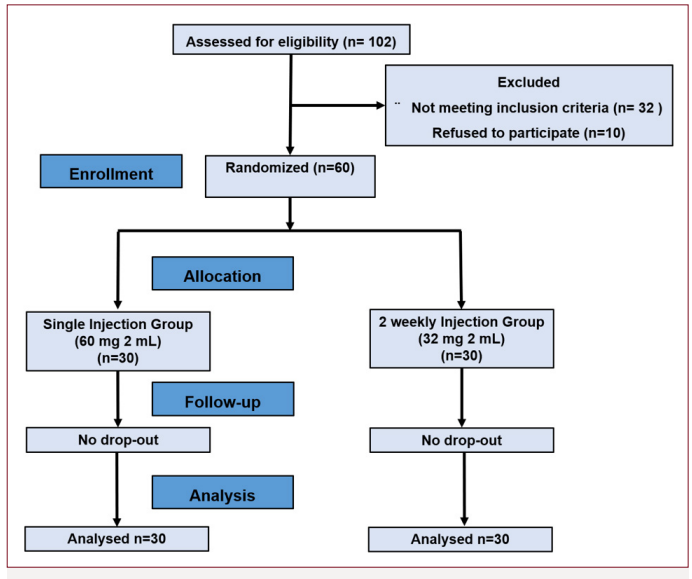

Figure 1. Flow diagram of the patients.

were lost in follow-up; thus, 60 patients were available for the final analysis. The two groups had no significant variations in baseline patient characteristics (Table 2).

Table 2. Demographic and baseline clinical characteristics of the patients

Variables	Single Dose (n=30)	Two-weekly (n=30)	p
Age (years±SD)	56.6±8.9	58.4±8.1	0.400
Sex (n/%)			0.191
Male	10 (33.3%)	6 (20%)	
Female	20 (66.6%)	24 (80%)	
Side			0.398
Right	14 (46.6%)	16 (53.3%)	
Left	16 (53.3%)	14 (46.6%)	
Height (cm±SD)	165.5±8.8	161.3±7.7	0.059
Weight (kg±SD)	83.3±13.8	80.7±15.1	0.497
BMI (kg/m^2±SD)	30.4±5.0	30.9±5.1	0.702
OA Grade (n / %)			0.119
Grade II	27 (90%)	30 (100%)	
Grade III	3 (10%)	0 (0%)	
Initial VAS (points±SD)	5.8±1,3	5,3±1.3	0.113
Initial WOMAC (score±SD)	47.6±24.2	51.3±19.5	0.517

SD: standard deviation; BMI: body mass index; OA: Osteoarthritis; VAS: visual analog scale; WOMAC: Western Ontario and McMaster University Osteoarthritis Index.

Table 3. Changes in the VAS during the study period

Variables	Single Dose (n=30)	Two-weekly (n=30)	p
VAS Initial	5.8±1.3	5.3±1.3	0.113
VAS 1st month	3.5±1.4	3.2±0.9	0.249
VAS 3rd month	3.3±1.5	3.4±1.2	0.789
VAS 6th month	3.2±1.3	3.6±1.5	0.294
Repeated ANOVA, p	**0.001**	**0.001**	
MIC			0.217
Δ (Initial-Final) VAS<3 points	15	19	
Δ (Initial-Final) VAS ≥ 3 points	15	11	

VAS: visual analog scale; ANOVA: Analysis of variance; MIC: Minimal important change.

Repeated measurements of VAS showed a significant reduction throughout the follow-up in both groups (p=0.001) (Table 3). There was no significant difference between groups at each time point. Similarly, repeated measurements of WOMAC showed a significant improvement throughout the follow-up in both groups (p=0.001). However, the WOMAC score in the sixth month was significantly better in the single-dose HA injection group (Table 4). Considering MIC for VAS and WOMAC, both groups were similar (p=0.217 and p=0.500, respectively) (Fig. 2). An adequate pain reduction could not be achieved in more than half of the patients (56.6%), and almost half (45%) did not have a clinically significant increase in knee function at the final follow-up, according to MIC values.

No significant complications, such as septic arthritis or allergic reactions, were recorded during the study. Two patients in each group reported increased pain that immediately started following the injection and lasted one week after. All of these patients were obese patients with a wide knee diameter. This minor complication might be related to the difficulties during the injection. Since all injections were performed using anatomic landmarks by palpation, the needle might have penetrated the cartilage and subchondral bone, resulting in pain. No joint effusion or infection was observed in any of the patients. The total cost of the single injection treatment, including doctor visits, intraarticular injections and disposables, was 64 USD per patient, while the two weekly injection treatments cost 100 USD per patient in the authors' country.

Table 4. Changes in WOMAC score during the study period

Variables	Single Dose (n=30)	Two-weekly (n=30)	p
WOMAC Initial	47.6±24.2	51.3±19.5	0.517
WOMAC 1st month	32.2±18.0	35.5±13.4	0.416
WOMAC 3rd month	27.8±14.6	31.9±13.5	0.266
WOMAC 6th month	24.5±15.0	34.3±16.3	0.019
Repeated ANOVA p	**0.001**	**0.001**	
MIC			0.500
Δ (Initial-Final) WOMAC<17 points	13	14	
Δ (Initial-Final) WOMAC ≥ 17 points	17	16	

WOMAC: Western Ontario and McMaster University Osteoarthritis Index; ANOVA: Analysis of variance; MIC: Minimal important change.

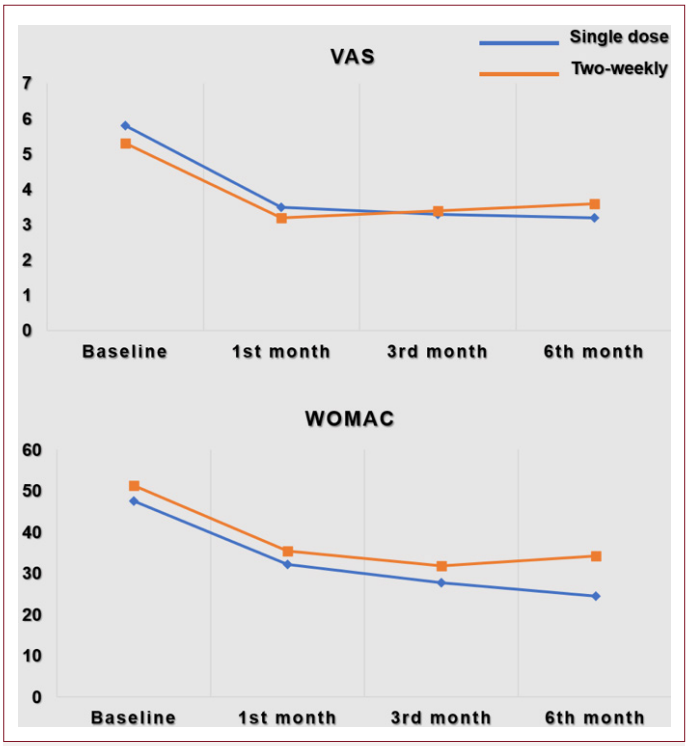

Figure 2. Baseline and follow-up VAS and WOMAC scores of the groups. The blue line designates the single-dose group, and the orange line designates the Two-weekly group.

DISCUSSION

This randomized clinical trial compared the effectiveness of a single dose versus two weekly injections of sodium hyaluronate in treating mild to moderate knee OA symptoms by measuring pain and knee function. The single-dose injection was 3% sodium hyaluronate at a volume of 2 ml and 60 mg, while the two weekly injections were 1.6% sodium hyaluronate at a volume of 2 ml and 32 mg each. The results of this study indicate that both regimens significantly decreased pain and improved knee function following the HA injection. The WOMAC score in the sixth month was significantly better in the group receiving a single HA injection dose. No significant complications that needed secondary intervention were observed. However, there was no significant difference between the groups regarding the MIC values for both VAS and WOMAC. An adequate pain reduction could not be achieved in more than half of the patients (56.6%), and almost half (45%) did not have a clinically significant increase in knee function at the final follow-up. Based on the findings in this study, a single-dose HA (60 mg, 2 ml) injection is not more effective in reducing pain and improving function in patients with knee OA compared to two weekly (32 mg, 2 ml) injections. Thus, the hypothesis was refuted. Nevertheless, the overall cost of treatment was cheaper in the single-dose injection group. Both regimens cannot sufficiently control pain and improve function; thus, the role of viscosupplementation in symptomatic knee OA is questionable.

Current research on the effectiveness of a single high-dose HA injection versus multiple lower-dose injections is controversial (Table 5). Some studies have found that a single high-dose injection is more effective at reducing pain and improving joint function than multiple lower-dose injections [15,20,23], while other studies have found no significant differences between the two regimens [17,19,21,22]. Furthermore, various other studies support consecutive injections to achieve sufficient pain control and improve function [11,12,16,18].

Conrozier et al. [15] reported on a randomized trial in 100 patients with knee OA, which aimed to assess five different dosing regimens of hylan G-F 20. Results showed that all treatment regimens resulted in statistically significant improvements in WOMAC index and VAS, with the single 6 mL injection and the three times 2 mL injections showing the most remarkable mean improvements. They proposed that a single 6 mL injection appears to be good, and this regimen could be developed as an alternative to multiple injections considering the risk/benefit ratio. Estades-Rubio et al. [20] compared the effectiveness and treatment cost of stabilized hyaluronic acid (NASHA) in a single injection with standard HA preparations in five injections. Results showed that NASHA was more effective than standard preparations in reducing pain, and there was a reduced need for analgesia during the six-month follow-up. Finally, Huang and Tsai [23] compared the efficacy and safety of a single injection of Cross-linked Hyaluronic Acid Platform Hyaluronan (CHAP-HA) with three injections of linear hyaluronan in knee OA patients. Results showed that CHAP-HA significantly improved VAS pain scores compared to linear-HA at week 26, with no significant differences in adverse events between the groups. Overall, these studies suggest that single-dose HA injections are effective and well-tolerated in reducing pain and improving function in knee OA patients.

Besides the abovementioned studies, four other clinical trials could not show any difference between single versus multiple injections [17,19,21,22]. Zhang et al. [17] compared the single versus multiple injections of two HA formulations, single-dose 3 mL high molecular weight hyaluronic acid (HMWHA), and five-weekly 2.5 mL low molecular weight hyaluronic acid (LMWHA), in 349 patients. The results showed that both treatments were efficacious, safe, and well-tolerated. Specifically, a single injection was non-inferior to five injections over 18 and 26 weeks for pain, physical function, global self-assessment, and

Table 5. Previous clinical trials that compared single versus multiple hyaluronic acid injection knee OA in the current literature

Author	Year	Design	# Patients	Regimen	Injection	Follow-up (weeks)	Recommendation
Conrozier et al. [15]	2009	RCT	Group 1: 20	Single dose	6 mL HMWHA	24	A single-dose regimen. might be recommended over multiple injections
			Group 2: 20	Single dose	4 mL HMWHA		
			Group 3: 19	Two-weekly	4 mL HMWHA		
			Group 4: 20	Three-weekly	4 mL HMWHA		
			Group 5: 19	Three-weekly	2 mL HMWHA		
Zoboli et al. [16]	2013	RCT	Group 1: 53	Single dose	6 mL IMWHA	12	No significant difference between the groups. Better pain control in three-weekly injections
			Group 2: 52	Three-weekly	2 mL IMWHA		
Zhang et al. [17]	2015	RCT	Group 1: 167	Single dose	3 mL HMWHA	26	No significant differences. between the groups
			Group 2: 165	Five-weekly	2.5 mL LMWHA		
Dıracoglu et al. [18]	2016	RCT	Group 1: 20	Single dose	4 mL IMWHA	24	Similar WOMAC Better pain in three-weekly injections
			Group 2: 20	Three-weekly	2.5 mL LMWHA		
Ha et al. [19]	2017	RCT	Group 1: 129	Single dose	3 mL XLHA	12	No significant differences between the groups.
			Group 2: 137	Three-weekly	2 mL HMWHA		
Estades-Rubio et al. [20]	2017	RCT	Group 1: 27	Single dose	3 mL HMWHA	26	Single dose is better than multiple injections
			Group 2: 27	Five-weekly	2.5 mL IMWHA		
Bahrami et al. [21]	2020	RCT	Group 1: 39	Single dose	3 mL HMWHA	24	No significant differences. between the groups
			Group 2: 40	Three-weekly	2 mL LMWHA		
Suppan et al. [22]	2020	RCT	Group 1: 62	Single dose	5 mL IMWHA	52	No significant differences. between the groups
			Group 2: 63	Three-weekly	2.5 mL IMWHA		
Huang and Tsai [23]	2021	RCT	Group 1: 58	Single dose	3 mL HMWHA	26	A single dose is better than multiple injections
			Group 2: 56	Three-weekly	2 mL LMWHA		
Current Study	2024	RCT	Group 1: 30	Single dose	2 mL IMWHA	26	No significant differences between the groups regarding MIC
			Group 2: 30	Two-weekly	2 mL IMWHA		

RCT: Randomized clinical trial, LMWHA: Low molecular weight hyaluronic acid, IMWHA: Intermediate molecular weight hyaluronic acid, HMWHA: High molecular weight hyaluronic acid.

knee stiffness. Ha et al. [19] compared the efficacy and safety of a single injection of cross-linked hyaluronate (XLHA) with three weekly injections of linear HMWHA in patients with knee OA. Two hundred eighty-seven patients were randomized to receive either XLHA or HMWHA injections. The study found that a single injection of XLHA was non-inferior to three weekly injections of linear HMWHA in reducing weight-bearing pain, with no significant differences in secondary endpoints and mild adverse events reported. Bahrami et al. [21] reported that a single injection of a cross-linked high-molecular-weight HA was equally effective as multiple linear low-molecular-weight HA (LMW-HA) injections in reducing pain and improving function during the two and 6-month follow-up periods. Similarly, Suppan et al. [22] found that a single large dose of intra-articular HA injection and three repeated smaller doses had comparable effectiveness over 12 months, but the single-dose regimen was associated with lower total treatment costs.

Contradictory findings are also reported in systematic review and meta-analysis studies investigating HA injection dosing regimens. Concoff et al. [12] reviewed the clinical trials on the effectiveness and safety of HA injections compared to placebo saline injections for knee OA. The review revealed that 2-4 injections of HA provided the most significant pain relief compared to saline injections, while single HA injections were not effective. Saline injections were generally safe, although five or more injections were linked to an increased risk of treatment-related adverse events. McElheny et al. [13] found no consistent difference in patient-reported outcomes between single and multiple-injection formulations, and single-injection formulations were more cost-effective and less inconvenient for patients. Another systematic review that aimed to assess the long-term effectiveness and safety of hylan G-F 20 injections for knee OA found similar efficacy of single or 1-3 weekly injections [14]. In contrast, Altman et al. [11] concluded that repeated courses of treatment provided sustained control of pain or further reduced it throughout the follow-up.

Some authors argue that HA injections are ineffective in treating symptomatic knee OA. In a recent systematic review and meta-analysis of randomized trials evaluating the effectiveness and safety of viscosupplementation for knee OA treatment, it is reported that viscosupplementation leads to a slight reduction in knee OA pain compared with placebo. The difference was less than the minimal clinically important between-group difference, and it is also associated with an increased risk of serious adverse events compared with a placebo [31]. Another meta-analysis concluded that viscosupplementation has a minimal or non-existent positive effect on pain and function in patients with knee OA and poses an increased risk of serious and local adverse events [32]. Similarly, the findings of our study confirm these results, although no significant adverse reactions were seen. Patients in both groups did not significantly benefit from treatment. The recent guideline on managing knee OA reported by the American Academy of Orthopaedic Surgeons (AAOS) also recommended against the routine use of HA in patients with knee OA [33].

There are some strengths and limitations of this study. A limitation of this study is the relatively small sample size, which may limit the generalizability of the results. In addition, the lack of blinding of both patients and clinicians could introduce bias, as expectations of treatment efficacy could influence the reported results. The study also did not include a placebo group, which may have provided a clearer understanding of the effects of HA injections compared to no treatment. Finally, variability in patient compliance and response to pain assessment tools such as VAS and WOMAC may have influenced the results. Despite these limitations, this trial has notable strengths. It is a randomized controlled trial with a robust design, including well-defined inclusion and exclusion criteria, which increases the reliability of the results. The comparison of two different HA injection regimens provides valuable evidence for clinical decision-making in the treatment of knee OA. In addition, the study's adherence to standardized radiological and functional assessment methods supports the consistency and validity of the results, providing a meaningful contribution to the ongoing debate on the efficacy of single versus multiple HA injections in the treatment of OA.

CONCLUSION

In conclusion, this study compared the effectiveness of a single dose versus two weekly injections of sodium hyaluronate in treating mild to moderate knee OA symptoms. Both regimens might provide a slight reduction in pain and improvement in knee function without reaching clinical significance. Half of the patients did not achieve adequate pain reduction and had a clinically significant increase in knee function. Therefore, the study suggests that the effectiveness of viscosupplementation in treating symptomatic knee OA is questionable and uncertain. Further studies might focus on selecting the patients who will benefit from the viscosupplementation in knee OA.

DECLARATIONS

Ethics Committee Approval: The Antalya Training and Research Hospital Clinical Research Ethics Committee granted approval for this study (date: 07.11.2019, number: 24/2).

Author Contributions: Idea/Concept – AB, MU; Design – AB, MU; Control/Supervision – AB, MU; Data Collection and/or Processing – AB, MU, MBE; Analysis and/or Interpretation – MU, OFE; Literature review – MBE, AB; Writing – AB, MU, MBE, OFE; Critical Review – AB, MU, MBE, OFE; References and fundings – AB, MU, MBE, OFE; Materials – AB, MU, MBE

Data Avaliability Statement: The data that support the findings of this study are available from the corresponding author upon reasonable request.

Conflict of Interest: The authors had no conflict of interest to declare.

Informed Consent: Written informed consents were provided by the participants.

Use of AI for Writing Assistance: The authors declared that they had not used any type of generative artificial intelligence for the writing of this manuscript, nor for the creation of images, graphics, tables, or their corresponding captions.

Financial Disclosure: The authors declares that they have no relevant or material financial interests that relate to the research described in this paper.

Financial Disclosure: No funding was received for this study.

Peer-review: Externally peer-reviewed.

ABBREVIATIONS

AAOS - American Academy of Orthopaedic Surgeons

CHAP-HA - Cross-linked hyaluronic acid platform hyaluronan

HA - Hyaluronic acid

HMWHA - High molecular weight hyaluronic acid

IMWHA - Intermediate molecular weight hyaluronic acid

LMWHA - Low molecular weight hyaluronic acid

MIC - Minimal important change

NASHA - stabilized hyaluronic acid

OA – Osteoarthritis

PACS - Picture archiving and communication systems

PRP - Platelet-rich plasma

RCT - Randomized controlled clinical trial

VAS - Visual analog scale

WOMAC: Western Ontario and McMaster University Osteoarthritis Index

XLHA - Cross-linked hyaluronate

REFERENCES

1. Cui A, Li H, Wang D, Zhong J, Chen Y, Lu H. Global, regional prevalence, incidence and risk factors of knee osteoarthritis in population-based studies. EClinicalMedicine 2020;29-30:100587. [CrossRef]
2. Hunter DJ, Bierma-Zeinstra S. Osteoarthritis. Lancet 2019;393:1745–59. [CrossRef]
3. Kolasinski SL, Neogi T, Hochberg MC, Oatis C, Guyatt G, Block J, et al. 2019 American College of Rheumatology/ Arthritis Foundation guideline for the management of osteoarthritis of the hand, hip, and knee. Arthritis Care Res (Hoboken) 2020;72:149–62. [CrossRef]
4. Bannuru RR, Osani MC, Vaysbrot EE, Arden NK, Bennell K, Bierma-Zeinstra SMA, et al. OARSI guidelines for the non-surgical management of knee, hip, and polyarticular osteoarthritis. Osteoarthritis Cartilage 2019;27:1578–89. [CrossRef]
5. Temple-Wong MM, Ren S, Quach P, Hansen BC, Chen AC, Hasegawa A, et al. Hyaluronan concentration and size distribution in human knee synovial fluid: variations with age and cartilage degeneration. Arthritis Res Ther 2016;18:18. [CrossRef]
6. Moreland LW. Intra-articular hyaluronan (hyaluronic acid) and hylans for the treatment of osteoarthritis: mechanisms of action. Arthritis Res Ther 2003;5:54–67. [CrossRef]
7. Altman RD, Manjoo A, Fierlinger A, Niazi F, Nicholls M. The mechanism of action for hyaluronic acid treatment in the osteoarthritic knee: a systematic review. BMC Musculoskelet Disord 2015;16:321. [CrossRef]
8. Bellamy N, Campbell J, Robinson V, Gee T, Bourne R, Wells G. Viscosupplementation for the treatment of osteoarthritis of the knee. Cochrane Database Syst Rev 2006;2006:CD005321. [CrossRef]
9. Maheu E, Rannou F, Reginster JY. Efficacy and safety of hyaluronic acid in the management of osteoarthritis: Evidence from real-life setting trials and surveys. Semin Arthritis Rheum 2016;45 Suppl 4:S28–33. [CrossRef]
10. Altman R, Lim S, Steen RG, Dasa V. Hyaluronic acid injections are associated with delay of total knee replacement surgery in patients with knee osteoarthritis: Evidence from a large U.S. health claims database. PLoS One 2015;10:e0145776. [CrossRef]
11. Altman R, Hackel J, Niazi F, Shaw P, Nicholls M. Efficacy and safety of repeated courses of hyaluronic acid injections for knee osteoarthritis: A systematic review. Semin Arthritis Rheum 2018;48:168–75. [CrossRef]
12. Concoff A, Sancheti P, Niazi F, Shaw P, Rosen J. The efficacy of multiple versus single hyaluronic acid injections: A systematic review and meta-analysis. BMC Musculoskelet Disord 2017;18:542. [CrossRef]
13. McElheny K, Toresdahl B, Ling D, Mages K, Asif I. Comparative effectiveness of alternative dosing regimens of hyaluronic acid injections for knee osteoarthritis: A systematic review. Sports Health 2019;11:461–6. [CrossRef]
14. De Lucia O, Jerosch J, Yoon S, Sayre T, Ngai W, Filippou G. One-year efficacy and safety of single or one to three weekly injections of hylan G-F 20 for knee osteoarthritis: a systematic literature review and meta-analysis. Clin Rheumatol 2021;40:2133–42. [CrossRef]
15. Conrozier T, Jerosch J, Beks P, Kemper F, Euller-Ziegler L, Bailleul F, et al. Prospective, multi-centre, randomised evaluation of the safety and efficacy of five dosing regimens of viscosupplementation with hylan G-F 20 in patients with symptomatic tibio-femoral osteoarthritis: A pilot study. Arch Orthop Trauma Surg 2009;129:417–23. [CrossRef]
16. Zóboli AA, de Rezende MU, de Campos GC, Pasqualin T, Frucchi R, de Camargo OP. Prospective randomized clinical trial: single and weekly viscosupplementation. Acta Ortop Bras 2013;21:271–5. [CrossRef]
17. Zhang H, Zhang K, Zhang X, Zhu Z, Yan S, Sun T, et al. Comparison of two hyaluronic acid formulations for safety and efficacy (CHASE) study in knee osteoarthritis: a multicenter, randomized, double-blind, 26-week non-inferiority trial comparing Durolane to Artz. Arthritis Res Ther 2015;17:51. [CrossRef]

18. Dıracoglu D, Tunçay TB, Şahbaz T, Aksoy C. Single versus multiple dose hyaluronic acid: Comparison of the results. J Back Musculoskelet Rehabil 2016;29:881–6. [CrossRef]
19. Ha CW, Park YB, Choi CH, Kyung HS, Lee JH, Yoo JD, et al. Efficacy and safety of single injection of cross-linked sodium hyaluronate vs. three injections of high molecular weight sodium hyaluronate for osteoarthritis of the knee: A double-blind, randomized, multi-center, non-inferiority study. BMC Musculoskelet Disord 2017;18:223. [CrossRef]
20. Estades-Rubio FJ, Reyes-Martín A, Morales-Marcos V, García-Piriz M, García-Vera JJ, Perán M, et al. Knee viscosupplementation: Cost-effectiveness analysis between stabilized hyaluronic acid in a single injection versus five injections of standard hyaluronic acid. Int J Mol Sci 2017;18:658. [CrossRef]
21. Bahrami MH, Raeissadat SA, Cheraghi M, Rahimi-Dehgolan S, Ebrahimpour A. Efficacy of single high-molecular-weight versus triple low-molecular-weight hyaluronic acid intra-articular injection among knee osteoarthritis patients. BMC Musculoskelet Disord 2020;21:550. [CrossRef]
22. Suppan VKL, Tew MM, Wong BC, Chan HK, Chew YW, Tan CS, et al. One-year follow-up of efficacy and cost of repeated doses versus single larger dose of intra-articular hyaluronic acid for knee osteoarthritis. J Orthop Surg (Hong Kong) 2020;28:2309499019895029. [CrossRef]
23. Huang TL, Tsai CH. Safety and efficacy of single CHAP Hyaluronan injection versus three injections of linear Hyaluronan in pain relief for knee osteoarthritis: a prospective, 52-week follow-up, randomized, evaluator-blinded study. BMC Musculoskelet Disord 2021;22:572. [CrossRef]
24. Altman R, Asch E, Bloch D, Bole G, Borenstein D, Brandt K, et al. Development of criteria for the classification and reporting of osteoarthritis. Classification of osteoarthritis of the knee. Diagnostic and Therapeutic Criteria Committee of the American Rheumatism Association. Arthritis Rheum 1986;29:1039–49. [CrossRef]
25. Butcher NJ, Monsour A, Mew EJ, Chan AW, Moher D, Mayo-Wilson E, et al. Guidelines for reporting outcomes in trial reports: The CONSORT-outcomes 2022 extension. JAMA 2022;328:2252–64. [CrossRef]
26. Kellgren JH, Lawrence JS. Radiological assessment of osteo-arthrosis. Ann Rheum Dis 1957;16:494–502. [CrossRef]
27. Landis JR, Koch GG. The measurement of observer agreement for categorical data. Biometrics 1977;33:159–74. [CrossRef]
28. Tüzün EH, Eker L, Aytar A, Daşkapan A, Bayramoğlu M. Acceptability, reliability, validity and responsiveness of the Turkish version of WOMAC osteoarthritis index. Osteoarthritis Cartilage 2005;13:28–33. [CrossRef]
29. Lee JS, Hobden E, Stiell IG, Wells GA. Clinically important change in the visual analog scale after adequate pain control. Acad Emerg Med 2003;10:1128–30. [CrossRef]
30. Clement ND, Bardgett M, Weir D, Holland J, Gerrand C, Deehan DJ. What is the minimum clinically important difference for the WOMAC index after TKA? Clin Orthop Relat Res 2018;476:2005–14. [CrossRef]
31. Pereira TV, Jüni P, Saadat P, Xing D, Yao L, Bobos P, et al. Viscosupplementation for knee osteoarthritis: Systematic review and meta-analysis. BMJ 2022;378:e069722. [CrossRef]
32. Rutjes AW, Jüni P, da Costa BR, Trelle S, Nüesch E, Reichenbach S. Viscosupplementation for osteoarthritis of the knee: a systematic review and meta-analysis. Ann Intern Med 2012;157:180–91. [CrossRef]
33. Brophy RH, Fillingham YA. AAOS clinical practice guideline summary: Management of osteoarthritis of the knee (nonarthroplasty), third edition. J Am Acad Orthop Surg 2022;30:e721–9. [CrossRef]

TUSYAD STArt Sports Traumatology & Arthroscopy

DOI: 10.14744/start.2024.13032
Sports Traumatol Arthrosc 2024;1(1):33-42

Review

Surgical Treatment of Symptomatic Bipartite Patella: A Case Report and Review of the Current Literature

Murat Yuncu, Omer Faruk Egerci, Firat Dogruoz

Department of Orthopedics and Traumatology, University of Health Sciences, Antalya Training and Research Hospital, Antalya, Türkiye

ABSTRACT

Although bipartite patella is accepted as a normal anatomic variant, it might occasionally cause anterior knee pain. The symptomatic bipartite patella can primarily benefit from conservative methods. However, all conservative treatment methods may fail in some cases, and surgical treatment may be necessary in these refractory cases. Herein, a 26-year-old male patient with symptomatic bipartite patella is presented. Despite using anti-inflammatory medications, rest, ice application, and activity modification, the patient's complaints did not regress at the 6-month follow-up. Open surgical excision of the fragment was performed, and the patient returned to his routine daily activities without restriction. Since refractory symptomatic bipartite patella is rare, there has yet to be a consensus on the optimal surgical treatment method. This article aims to present an extensive literature search to discuss all aspects of surgical treatment of symptomatic bipartite patella.

Keywords: Anterior knee pain, bipartite patella, open excision, surgical treatment, symptomatic bipartite patella

Cite this article as:
Yuncu M, Egerci OF, Dogruoz F. Surgical Treatment of Symptomatic Bipartite Patella: A Case Report and Review of the Current Literature. Sports Traumatol Arthrosc 2024;1(1):33-42.

Address for correspondence:
Murat Yuncu.
Department of Orthopedics and Traumatology, University of Health Sciences, Antalya Training and Research Hospital, Antalya, Türkiye
E-mail: m-yuncu@yandex.com

Submitted: 04.07.2024
Revised: 23.10.2024
Accepted: 24.10.2024
Available Online: 28.11.2024

Sports Traumatology & Arthroscopy – Available online at www.stajournal.com

This work is licensed under a Creative Commons Attribution-NonCommercial 4.0 International License.

INTRODUCTION

Ossification of the patella begins between the ages of 3 to 5, often with a single central ossification nucleus [1,2]. Around the age of 12, secondary ossification centers may arise during the ossification of the patella [3–5]. A distinctive patella is formed when the primary and secondary ossification centers fuse [6]. However, the bipartite or tripartite patella occurs when these ossification centers fail to unite and remain separate [2,3,7,8]. Bipartite patella is recognized as a common anatomic variation or developmental variant of the patella and is typically detected incidentally on knee radiographs collected for various purposes while remaining asymptomatic. The incidence of the bipartite patella in the general population is around 1-2% [1,9,10].

Bipartite patella is usually asymptomatic and remains silent in most patients [11–13]. Although the exact pathophysiology of why an asymptomatic bipartite patella becomes symptomatic is not clarified, chronic repetitive microtrauma on the synchondrosis and the resulting inflammation is responsible for the symptoms [4,14]. In other words, the symptomatic bipartite patella can be considered an overuse syndrome [15,16]. Since bipartite patella is a relatively rare anatomic variant, the symptomatic bipartite patella is an even less common clinical condition.

As with all overuse syndromes, the symptomatic bipartite patella can primarily benefit from conservative methods, such as rest and activity modification, cryotherapy, physical therapy,

and nonsteroidal anti-inflammatory medications [17–21]. These methods aim to unload the extensor mechanism of the knee joint, reduce inflammation, and control pain. However, all conservative treatment methods may fail in some cases, and surgical treatment may be necessary in these refractory cases.

To date, various surgical treatment options have been utilized, such as open or arthroscopic excision [7,11,12,22–24], lateral retinacular release [25–29], and internal fixation of the fragment [6,14,30–33]. However, due to the rarity of symptomatic cases, high-level evidence supporting one technique over another is limited, and current recommendations are based primarily on small case series and expert opinions [8,34]. This lack of consensus highlights a critical gap in the literature that this case report and accompanying review aim to address.

The present study seeks to add clarity by presenting a case of successful treatment with open fragment excision in a patient with symptomatic bipartite patella. Additionally, this review of the literature aims to provide a comprehensive synthesis of the available surgical options, focusing on the outcomes, indications, and complications of each approach. By highlighting both the strengths and limitations of existing techniques, this report contributes to the ongoing discussion regarding the optimal management of refractory symptomatic bipartite patella.

CASE PRESENTATION

A 26-year-old construction worker presented to the outpatient clinic complaining of anterior knee pain. His pain had started four months ago and was particularly aggravated following heavy activities that required kneeling and squatting. Apart from the pain, there was also occasional crepitation over the patella. He was otherwise healthy, and his past medical history revealed nothing abnormal. On physical examination, mild swelling or protrusion was observed over the superolateral corner of the patella. The active and passive ranges of motion were within normal limits, and the knee was stable. There was tenderness over the swelling on palpation, and the patellar grinding test was positive.

Direct radiographic knee imaging showed no significant pathology except for a bipartite patella (Fig. 1). Based on the physical examination and direct radiographic findings, the diagnosis of the symptomatic bipartite patella was suspected. Magnetic resonance imaging (MRI) of the knee joint was requested to confirm the provisional diagnosis and to detect other possible pathologies explaining the patient's complaints. MRI examination demonstrated marked intraosseous edema within the bipartite patella fragment and the synchondrotic articulation. The rest of the knee joint was reported as normal (Fig. 2).

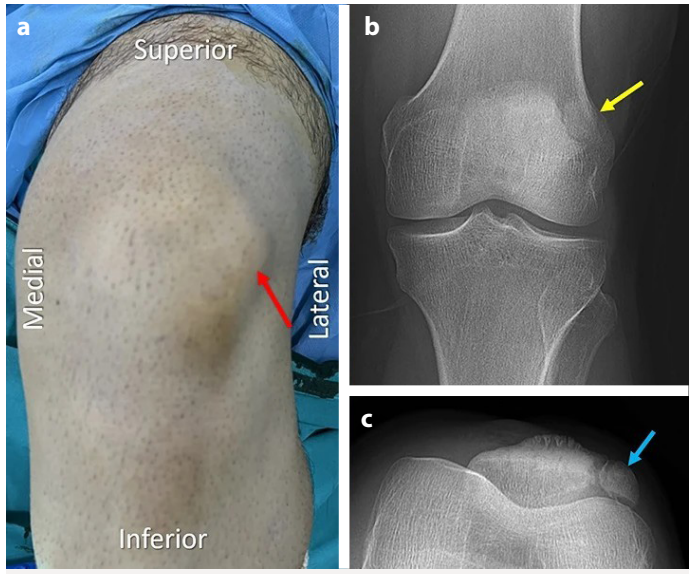

Figure 1. (a) Clinical appearance of the knee from the anterior aspect (red arrow shows the bony prominence caused by the bipartite patella fragment). **(b)** anteroposterior, and **(c)** tangential knee radiographs showing the bipartite patella (yellow and blue arrows).

As MRI findings supported our clinical diagnosis, the patient was diagnosed with symptomatic bipartite patella. Conservative treatment consisting of activity restriction, knee brace during kneeling, and non-steroid anti-inflammatory drug therapy was initiated. Despite three months of conservative treatment, there was no significant improvement in the patient's complaints. A local anesthetic injection was made around the bipartite fragment and synchronistic joint to understand whether the patient would benefit from surgical excision. Immediately after the simulation test, the patient's complaints disappeared. Thereupon, surgical excision was planned for the patient. Although the standard duration of conservative treatment can vary, in this case, three months was deemed sufficient due to the patient's persistent symptoms and the clear benefit observed from the local anesthetic injection, indicating that surgery was appropriate.

First, diagnostic knee arthroscopy was performed by applying a tourniquet to the thigh under spinal anesthesia. The articular cartilage of the patella was intact, and the patellofemoral joint movements were normal on dynamic examination (Fig. 3). After the arthroscopic examination, a longitudinal incision was made over the superolateral corner of the patella. During deep dissection, it was observed that a significant part of the vastus lateralis tendon was inserted into the bipartite patella fragment. The fragment was separated from the synchondrosis and surrounding soft tissues by sharp dissection. The fragment

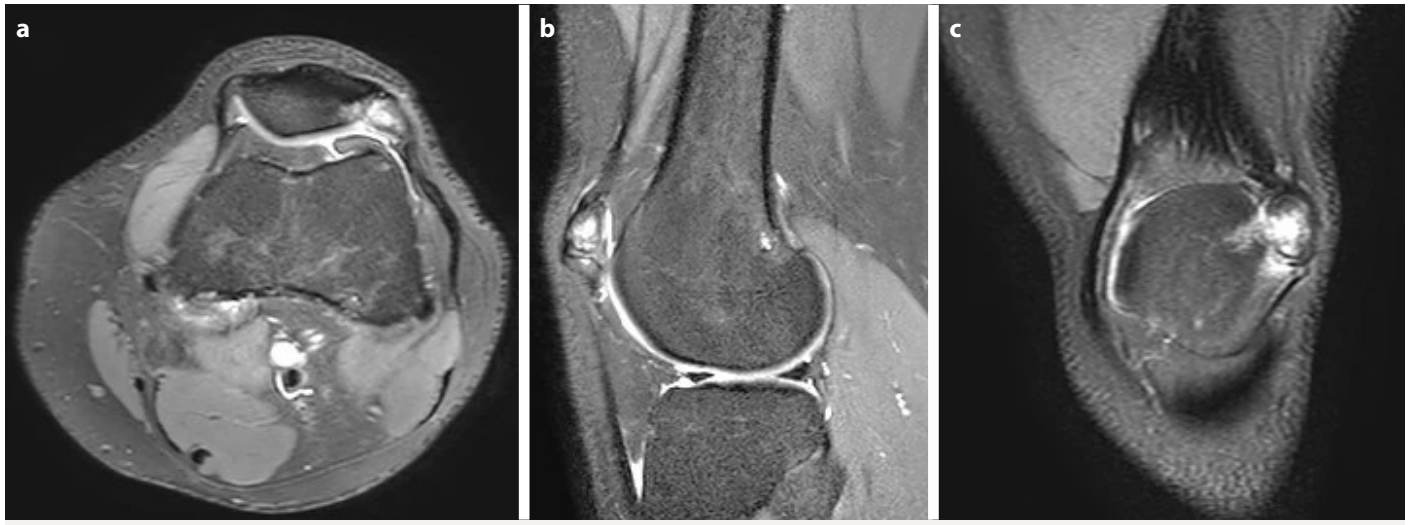

Figure 2. (a) Axial and **(b)** sagittal Proton density weighted (PDW), **(c)** coronal T2 weighted MR images show bone marrow edema within the bipartite patella and adjacent area to synchondrosis.

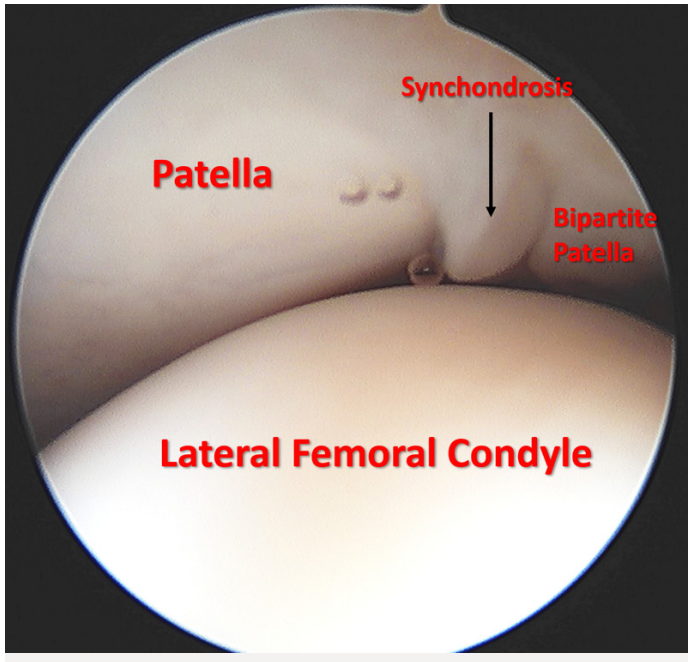

Figure 3. Arthroscopic image showing the patella, synchondrosis, bipartite fragment and lateral femoral condyle from the anteromedial portal.

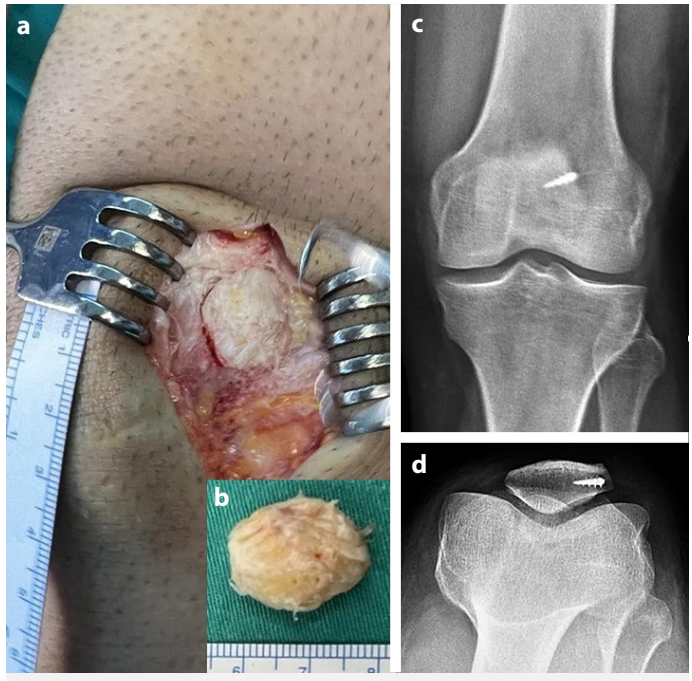

Figure 4. (a) Intraoperative appearance of the fragment before removal. **(b)** Bipartite patella fragment after excision. **(c)** Anteroposterior **(d)** tangential knee radiographs showing metallic anchors and total removal of the fragment without residue.

was about 2 x 2 cm in size. The synchondrotic joint was curetted down to the spongious bone, and the vastus lateralis tendon was sutured to the patella using a metal anchor (Fig. 4).

The postoperative period was uneventful. Full weight-bearing, active and passive knee range of motion exercises were started immediately on the second postoperative day. Sutures were removed at the end of the second week. At the sixth-week follow-up, knee ROM was painless and similar to the contralateral side. At the final follow-up six months after the surgery, the patient had no pain and returned to his previous

level of activity and work. Lysholm knee score was excellent (100 points).

Literature Search

A comprehensive review of the literature was conducted to find all studies that assessed surgical treatment for symptomatic bipartite patella from 1950 to the present. The following electronic databases were searched: CINAHL, MEDLINE, PubMed, Scopus, Google Scholar, and SPORTDiscus. 'Bipartite patella' was used as the search term, and only articles written in English were reviewed. Duplications, studies reporting conservative treatment, review articles, systematic reviews, and surgical technique papers that do not report details of patients were excluded. A total of 44 papers were eligible for the analysis [3–7,11–17,21–33,35–52].

Literature Search Results

Table 1 summarizes the previously published studies that report surgical treatment of bipartite patella. There were 205 patients in 44 publications [3–7,10–17,21–33,35–46,48,49,51,52]. Since some studies did not report detailed demographic data, descriptive statistics were calculated based on the available data. The mean age was 20.46 years (range, 10-69 years). There were 149 (75%) male and 50 (25%) female patients. The right side was involved in 83 (49%), the left side in 81 (48%), and bilateral involvement in 5 (3%) patients. Various surgical techniques were used for the treatment (Table 1). The treatment outcomes were reported for 205 patients. 192 (93.5%) patients had complete relief of symptoms, and 8 (4%) had occasional pain.

Only in one (0.5%) patient, the symptoms did not resolve following open excision of the fragment. However, this patient had additional patellofemoral osteoarthritis and diffuse cartilage lesion; thus, a partial patellectomy [13] had to be performed. Four patients required secondary revision surgery [6], including lateral release (0.5%), excision of the residual fragment (0.5%), and removal of fixation screws in two cases (1%).

DISCUSSION

The most important finding of this study is that open fragment excision provided complete relief of symptoms in a patient with refractory symptomatic bipartite patella, allowing a return to full activity without any restrictions. This outcome is consistent with the findings of most previous studies, which report excellent results following surgical excision in cases where conservative treatment fails. Our literature review further supports excision as an effective treatment option, particularly in cases where the fragment is small and located outside the patellofemoral joint. Additionally, while various surgical techniques—such as lateral retinacular release and fragment fixation—are available, no single method has demonstrated clear superiority, emphasizing the importance of individualized treatment based on the fragment's characteristics and the surgeon's expertise. In the following paragraphs, we will discuss the findings of this case in light of the existing literature on bipartite patella and its treatment options.

Diagnosis and Surgical Indication

The first radiological examination is usually direct radiographic imaging for a patient presenting with anterior knee pain since it is inexpensive and quickly accessible. The detection of the bipartite patella is generally made on radiographs, especially tangential views. However, radiological detection does not establish the relationship between anterior knee pain and the bipartite patella. Since it is an asymptomatic normal variant, it must be objectively determined that the complaints originate from the bipartite patella. In other words, other causes of anterior knee pain should be carefully excluded before a diagnosis of the symptomatic bipartite patella. MRI is the most valuable imaging modality in confirming the diagnosis of the symptomatic bipartite patella. Kavanagh et al. [53] reviewed MRI findings of 53 patients with a bipartite patella. They reported that identifying bone marrow edema at or adjacent to the bipartite fragment by MRI was the sole imaging finding that reflects a scenario where the bipartite patella is the primary cause of symptomatology. Secondly, an MRI allows for a thorough screening of the knee joint and excludes other possible causes explaining the anterior knee pain. Kavanagh et al. [53] found other reasons explaining anterior knee pain in a significant proportion of bipartite patella cases (72%) without accompanying edema. Apart from MRI, scintigraphy might be an alternative method for confirming the diagnosis, but due to its low specificity, this method is a limited technique.

The initial treatment of symptomatic bipartite patella is conservative. Surgical treatment should be considered in patients for whom conservative treatment is insufficient to relieve symptoms. Before deciding on surgical intervention, local anesthetic injections provide valuable insight into whether the patient will benefit from surgical treatment. The regression of symptoms with a local anesthetic injection around the bipartite fragment strengthens the indication for surgery.

In case of a positive history of trauma, a vertical patella fracture should be kept in mind and excluded [21,30,42]. Although the clinical findings are different, the radiographic appearance of these two entities resembles each other (Fig. 5). In bipartite patella, the synchondrosis is rounded and irregular, but the fracture usually extends distally and is sharp-edged.

Table 1. Previous cases and case series that reported surgical treatment of bipartite patella in current literature

Author	Year	# Cases	Sex	Age (years) Mean/range	Side	Treatment
Green [16]	1975	3	3 M	14.3 (13-15)	3 R	Open excision
Halpern and Hewitt [5]	1978	1	F	20	Bilateral	Open excision
Weaver [13]	1977	16	12 M, 4 F	19 (12-42)	NR	Open excision
Ogden et al. [4]	1983	1	M	15	L	Open excision
Yamaguchi et al. [35]	1990	6		17.8 (14-25)	5 R,1 L	Open excision
Bourne and Bianco [36]	1990	16	12 M, 4 F	14.5 (11,5-19)	8 R,8 L	Open excision
Ogata [37]	1994	13	10 M, 3 F	21	6L,5R,2B	Open excision
Eberhard et al. [38]	1995	1	M	44	NR	Open excision
Ireland and Chang [39]	1995	1	M	47	Left	Diagnostic arthroscopy followed by open excision
Iossifidis and Brueton [12]	1995	7	3 F, 4 M	30 (21-46)	Unilateral	Arthroscopic excision
Mori et al. [27]	1995	15	9 M, 6 F	16.6 (13-24)	8L,6R,1B	Modified lateral release with extension to proximal attachment of separated fragment
Kumar et al. [29]	1999	1	M	36	L	Lateral release & Medial plication
Tashiro et al. [40]	2002	1	M	41	L	Open excision
Adachi et al. [41]	2002	12	10 M, 2 F	15.6 (12-28)	7R,5L	Arthroscopic VL release
Canizares and Selesnick [3]	2003	1	M	32	R	Diagnostic arthroscopy followed by open excision
Okuno et al. [21]	2004	1	M	16	R	ORIF (Tension band wiring)
Azarbod et al. [11]	2005	1	M	26	R	Arthroscopic excision
Morrison et al. [7]	2006	1	M	20	L	Open excision
Enomoto et al. [24]	2006	1	M	32	R	Open excision
Tauber et al. [42]	2006	1	F	18	L	ORIF (Tension band wiring)
Gorva et al. [33]	2006	1	M	69	R	ORIF (with anchors)
Thomas et al. [43]	2007	1	F	40	R	Open excision of fragment; repair of quadriceps tendon
Woods et al. [44]	2007	1	M	44	L	Open excision of fragment; repair of quadriceps tendon
Tonotsuka and Yamamoto [32]	2008	1	M	66	L	ORIF (fragment with compression screws; repair of quadriceps tendon)
Yoo et al. [45]	2008	1	M	37	R	Arthroscopic excision
Weckström et al. [17]	2008	25	25 M	15 (10-22)	13R,12L	Open excision (n:24), Arthroscopic excision(n:1)
Carney et al. [22]	2010	1	M	26	R	Arthroscopic excision
Felli et al. [23]	2011	1	F	22	NR	Arthroscopic excision
Peek and Bary [46]	2012	1	M	12	R	Arthroscopic excision
Werner et al. [47]	2013	3	1 F, 2 M	16, 21, 36	2 R, 1 L	Arthroscopic excision (n=2) ORIF (screws fixation) (n=1)
Mohammad et al. [31]	2014	1	M	45	L	ORIF (screws fixation)

Table 1. Previous cases and case series that reported surgical treatment of bipartite patella in current literature (Cont.)

Author	Year	# Cases	Sex	Age (years) Mean/range	Side	Treatment
Vaishya et al. [48]	2015	5	5 M	21 (16-31)	2 R, 3 L	Arthroscopic excision (n=3) ORIF (screws fixation) (n=2)
Kaas and van der Werf [49]	2015	1	F	23	R	Open excision
Radha et al. [30]	2017	6	6 M	19, 26	NR	ORIF (screws fixation)
James et al. [50]	2017	1	M	16	L	Arthroscopic excision
Felli et al. [25]	2018	10	10 M	20.5 (19-27)	5 R, 5 L	Arthroscopic VL release
Seguritan et al. [51]	2018	1	M	36	R	Open excision of fragment; repair of quadriceps tendon
Saleh et al. [52]	2019	1	M	26	L	Open excision and LRR
Kallini et al. [6]	2021	27	16F,11M	15.4 (10-20)	9R,18L	Open excision (n=9), Open excision with a lateral release (n=8), Isolated lateral release (n=5), ORIF (n=4), Synchondrosis drilling (n=1)
Gupta et al. [28]	2021	1	M	16	L	Subperiosteal VL release
Naikoti and Thonse [14]	2021	1	M	32	L	ORIF (tension band wiring)
Pan and Hennrikus [15]	2022	8	2 F, 6 M	37.7 (21-63)	4 R, 4 L	Open excision (n=1) Diagnostic arthroscopy followed by open excision (n=6) Diagnostic arthroscopy followed by open excision with a lateral release (n=1)
Pan and Hennrikus [26]	2022	6	3 F, 3 M	15.8 (13-17)	3 R, 2 L, 1 Bilateral	Open excision (n=2) Complete lateral release, (n=1) Open excision with a complete lateral release (n=2) Open excision with a partial lateral release (n=2)

M: Male; F: Female; R: Right; L: Left; B: Bilateral; VL: Vastus Lateralis; ORIF: Open reduction internal fixation.

Surgical Treatment

Various surgical treatment modalities have been reported for the bipartite patella, including open and arthroscopic techniques [10,15,30]. However, these methods might be categorized into three main groups: (1) excision of the fragment, (2) lateral release, and (3) fixation of the fragment, respectively. There are no strict indications of the above-mentioned surgical techniques that favor one over the other. In the current extensive literature review, clinical results were satisfactory in almost all patients (96%), regardless of the surgical technique. Nevertheless, some authors proposed that removing the fragment that involves more than 40% of the patellar articular surface deteriorates the functions of the extensor mechanism. In such cases, it is recommended to choose techniques to preserve the fragment, such as lateral release or fragment fixation. In our case, the fragment covered a small part of the entire articular surface and was located outside the patellofemoral joint [6]. Therefore, there was no contraindication for its removal. In general, evaluating fragment size and location may be advisable before deciding on the optimal surgical technique.

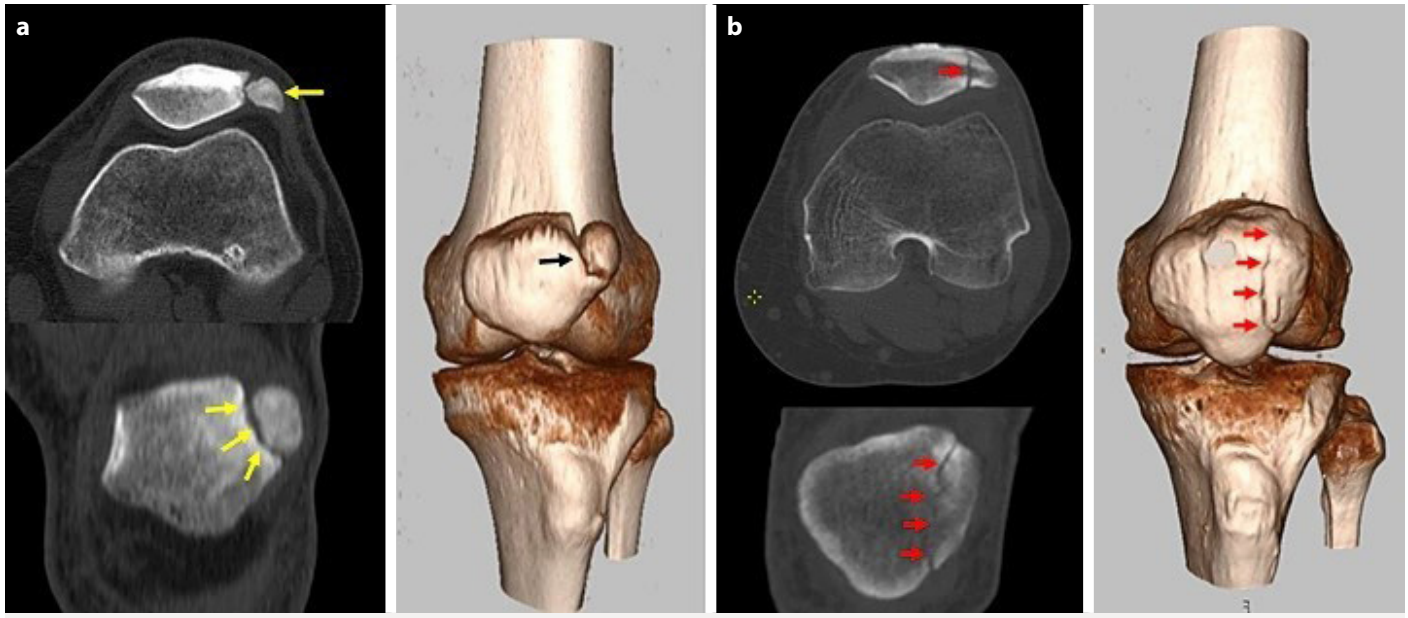

Figure 5. Axial, coronal, and 3D images of the **(a)** bipartite patella and **(b)** vertical patellar fracture. Please note the significant differences between the synchondrosis and fracture line (arrows).

Surgical Excision of the Fragment (Open and Arthroscopic)

Surgical excision was the most common treatment method among the reported cases. In the present review, open excision was performed in 112 knees (97 had isolated open excision, 4 had open excision followed by quadriceps tendon reattachment, and the remaining 11 had open excision simultaneous lateral release). Arthroscopic excision was chosen in 16 knees. Open excision is a relatively simple procedure that requires no special instrument, advanced surgical set-up, or advanced surgical skills [24,37,52,54]. Moreover, simultaneous repair of the quadriceps tendon is easy to perform. Since the surgical field is under direct vision, the risk of leaving residual tissue is low. However, compared to arthroscopic excision, it requires a longer period for recovery, patients have larger incision scars, and the risk of infection is greater [10,11,22,23,55,56]. On the other hand, arthroscopic visualization of the knee joint provides a second chance to examine and rule out the other pathologies that might cause anterior knee pain. Therefore, some authors have recommended initial diagnostic arthroscopy followed by open excision. This approach is highly recommended since it is safe and prevents undertreatment.

Lateral Release

The second most common technique was lateral retinacular release and its modifications. This treatment aims to eliminate the chronic repetitive traction applied to the bipartite patella synchondrosis by the extensor mechanism, which is thought to be the etiology of the complaints. In addition, if the fragment is relatively large and forms a significant part of the articular surface (>40%), this technique can be applied to preserve this fragment rather than remove it. Modified techniques such as complete lateral release, partial lateral release, vastus lateralis release, and subperiosteal vastus lateralis release have been used in the literature, either open or arthroscopically [25,27,28,41]. The lateral release has two major disadvantages. First, it might create iatrogenic medial instability, and second, possible muscle weakness due to discontinuity in the extensor mechanism [26,29]. To avoid this effect, the authors recommend only isolated vastus lateralis release. Thus, the amount of release should be properly adjusted. In the case series reported by Felli et al. and Adachi et al. [25,41], 22 patients underwent arthroscopy-assisted vastus lateralis release to avoid complications of complete lateral release. Many cases of spontaneous fusion have been observed because chronic repetitive traction is eliminated. To preserve the continuity of the tendon-periosteum complex with the patella, Ogata described a modified technique for subperiosteal release of the vastus lateralis from the accessory fragment [37]. The procedure's goal is to reduce mobility in the synchondrosis caused by traction of the vastus lateralis muscle, which is the same as the goal of a lateral retinacular release. However, this approach lessens the tension imbalance between the medial and lateral retinacula, iatrogenic medial instability, and vastus lateralis weakening [26,27,41].

Fixation of the fragment

The bipartite patella is not an accessory element; rather, it is the main component of the patella since it occurs due to a lack

of fusion in secondary ossification centers. Thus, removing a large bipartite patella fragment (>40%) weakens the extensor mechanism and distorts the patellar articular surface. Fixation of the fragment might be a better option when the fragment is large. Moreover, some authors favored this technique in the acute traumatic separation of the bipartite patella. In this review, open reduction and internal fixation (ORIF) were performed in 15 patients. Screws were used in 11 patients, tension band wiring was used in three patients, and a suture anchor was used in one patient as fixation material.

Fixation of the fragment targets the fusion of the fragment with the patella. Synchondrosis tissue should be carefully removed, and bleeding bony tissue should be exposed, similar to pseudoarthrosis surgery [30,31,42]. The advantage of ORIF is the preservation of the articular surface and structure of the patella. Besides, it has several disadvantages. Postoperative immobilization, longer recovery and regaining muscle strength, wound healing problems, and infection can be listed as significant disadvantages [32,33]. Theoretically, the failure of fusion is a risk. Finally, implant removal surgery late after union might be necessary.

Other Surgical Techniques

In addition to the above-mentioned primary surgical techniques, a few authors described other methods. Kallini et al. [6] performed arthroscopic synchondrosis drilling on one patient. The basic principle behind this technique is the induction of union by increasing vascular nourishment of the synchondrosis. Some cases were treated using a combination of the techniques mentioned above, such as surgical excision of the fragment combined with lateral retinacular release and lateral release combined with medial plication [3,27].

Limitations

This case report has several limitations. First, the follow-up period of six months may not be sufficient to assess the long-term outcomes of surgical excision in the symptomatic bipartite patella, and a longer follow-up is needed to confirm the durability of the results. Second, no pre-operative scoring was performed, which limits the ability to objectively compare the patient's condition before and after the surgery. Lastly, while this report highlights a successful case of open fragment excision, the study's findings are based on a single patient, and further research with larger patient cohorts is necessary to validate the results and provide more substantial evidence for surgical decision-making.

CONCLUSION

Bipartite patella is relatively easy to diagnose; however, diagnosing symptomatic bipartite patella requires additional examination and imaging, with MRI being the most valuable diagnostic tool. Bone marrow edema within the fragment and around the synchondrosis is a key indicator, especially after excluding other pathologies. Conservative treatment is the first-line approach, and patients should be followed for a sufficient period to allow for symptom relief. For cases that do not respond to conservative management, a local anesthetic injection can help determine the potential benefit of surgical intervention. In our case, surgical excision provided complete symptom relief and allowed the patient to return to full activity. The literature supports surgical excision as a valid option for refractory symptomatic bipartite patella, with low complication rates reported across different techniques. Although no single surgical method has demonstrated clear superiority, the choice of technique can be tailored to the surgeon's experience, available instrumentation, and the characteristics of the fragment. Finally, diagnostic arthroscopy should be performed at the start of the operation to assess intra-articular pathologies, which may complement MRI findings.

DECLARATIONS

Ethics Committee Approval: Not applicable.

Author Contributions: Idea/Concept – MY, OFE; Design – FD, OFE; Control/Supervision – MY, OFE; Data Collection and/or Processing – FD; Analysis and/or Interpretation – MY; Literature review – OFE, FD; Writing – MY; Critical Review – MY, FD; References and fundings – MY, FD; Materials – OFE

Data Avaliability Statement: The data that support the findings of this study are available from the corresponding author upon reasonable request.

Conflict of Interest: The authors declared that they have no competing interests.

Informed Consent: Written informed consent was obtained from the patient to the anonymous use of the imaging files.

Use of AI for Writing Assistance: The authors declared that they had not used any type of generative artificial intelligence for the writing of this manuscript, nor for the creation of images, graphics, tables, or their corresponding captions.

Financial Disclosure: The author declares that they have no relevant or material financial interests that relate to the research described in this paper.

Funding Disclosure: No funds have been received for this study.

Peer-review: Externally peer-reviewed.

ABBREVIATIONS

MRI - Magnetic resonance imaging

ORIF - Open reduction and internal fixation

VL - Vastus lateralis

REFERENCES

1. McMahon SE, LeRoux JA, Smith TO, Hing CB. The management of the painful bipartite patella: A systematic review. Knee Surg Sports Traumatol Arthrosc 2015;24:2798–805. [CrossRef]
2. Kose O, Eraslan A, Ergun A, Faruk Egerci O, Cevat Ercan E. Prevalence of bipartite patella in Turkish population. Analysis of bilateral knee radiographs in 897 subjects. Int J Morphol 2015;33:1108–13. [CrossRef]
3. Canizares GH, Selesnick FH. Bipartite patella fracture. Arthroscopy 2003;19:215–7. [CrossRef]
4. Ogden JA, McCarthy SM, Jokl P. The painful bipartite patella. J Pediatr Orthop 1983;2:263–9. [CrossRef]
5. Halpern AA, Hewitt O. Painful medial bipartite patellae. A case report. Clin Orthop Relat Res 1978;134:180–1. [CrossRef]
6. Kallini J, Micheli LJ, Miller PE, Kramer DE, Kocher MS, Heyworth BE. Operative treatment of bipartite patella in pediatric and adolescent athletes: A retrospective comparison with a nonoperatively treated cohort. Orthop J Sports Med 2021;9:2325967120967125. [CrossRef]
7. Morrison MJ, Coker CA, McGuire MS, Mickle AM. Symptomatic bipartite patella in a college football player. Human Kinetics 2006;11:51–3. [CrossRef]
8. Soini V, Raitio A, Virkki E, Syvänen J. Treatment of congenital bipartite patella in pediatric population - a systematic review of the published studies. Acta Orthop Belg 2022;88:87–93. [CrossRef]
9. O'Brien J, Murphy C, Halpenny D, McNeill G, Torreggiani WC. Magnetic resonance imaging features of asymptomatic bipartite patella. Eur J Radiol 2011;78:425–9. [CrossRef]
10. Floyd ER, Falaas KL, Carlson GB, Monson J, LaPrade RF. Arthroscopic excision of bipartite patella. Arthrosc Tech 2021;10:e1257–62. [CrossRef]
11. Azarbod P, Agar G, Patel V. Arthroscopic excision of a painful bipartite patella fragment. Arthroscopy 2005;21:1006. [CrossRef]
12. Iossifidis A, Brueton RN. Painful bipartite patella following injury. Injury 1995;26:175–6. [CrossRef]
13. Weaver JK. Bipartite patellae as a cause of disability in the athlete. Am J Sports Med 1977;5:137–43. [CrossRef]
14. Naikoti KK, Thonse R. New variant of bipartite patella with traumatic separation and complete disruption of the extensor mechanism of the knee. BMJ Case Rep 2021;14:1–5. [CrossRef]
15. Pan T, Hennrikus W. Symptomatic bipartite patella in adults treated with open excision: Outcomes and management. Cureus 2022;14:e26705. [CrossRef]
16. Green WT. A report of three cases. Clin Orthop Relat Res 1975;110:197–200. [CrossRef]
17. Weckström M, Parviainen M, Pihlajamäki HK. Excision of painful bipartite patella: Good long-term outcome in young adults. Clin Orthop Relat Res 2008;466:2848–55. [CrossRef]
18. Zerouali Boukhal Z, Belgadir H, Jadib A, Amriss O, Adam Fadoul A, Merzem A, et al. Painful bipartite patella following injury: a case report. Radiol Case Rep 2022;17:725–8. [CrossRef]
19. Marya KM, Yadav V, Devagan A, Kundu ZS. Painful bilateral bipartite patellae--case report. Indian J Med Sci 2003;57:66–7.
20. Gaheer RS, Kapoor S, Rysavy M. Contemporary management of symptomatic bipartite patella. Orthopedics 2009;32:843–9. [CrossRef]
21. Okuno H, Sugita T, Kawamata T, Ohnuma M, Yamada N, Yoshizumi Y. Traumatic separation of a type I bipartite patella: A report of four knees. Clin Orthop Relat Res 2004;420:257–60. [CrossRef]
22. Carney J, Thompson D, O'Daniel J, Cassidy J. Arthroscopic excision of a painful bipartite patella fragment. Am J Orthop (Belle Mead NJ) 2010;39:40–3.
23. Felli L, Fiore M, Biglieni L. Arthroscopic treatment of symptomatic bipartite patella. Knee Surg Sports Traumatol Arthrosc 2011;19:398–9. [CrossRef]
24. Enomoto H, Nagosi N, Okada E, Ota N, Iwabu S, Kamiishi S. Hemilaterally symptomatic bipartite patella associated with bone erosions arising from a gouty tophus: A case report. Knee 2006;13:474–7. [CrossRef]
25. Felli L, Formica M, Lovisolo S, Capello AG, Alessio-Mazzola M. Clinical outcome of arthroscopic lateral retinacular release for symptomatic bipartite patella in athletes. Arthroscopy 2018;34:1550–8. [CrossRef]
26. Pan T, Hennrikus WL. Outcomes of surgical treatment of symptomatic bipartite patella in teenage athletes. J Pediatr Orthop B 2022;31:371–5. [CrossRef]
27. Mori Y, Okumo H, Iketani H, Kuroki Y. Efficacy of lateral retinacular release for painful bipartite patella. Am J Sports Med 1995;23:13–8. [CrossRef]
28. Gupta A, Garg A, Sahu A, Yadav U, Malik M, Resident J, et al. A rare case of symptomatic bipartite patella in an adolescent male with review of literature and our experience. Int J Orthop Sci 2021;7:801–5. [CrossRef]
29. Kumar A, Iqbal MJ, Ali MS. Separation of bipartite patella in nail–patella syndrome: A case report. Knee 1999;6:67–9. [CrossRef]
30. Radha S, Shenouda M, Konan S, Lavelle J, Church S. Successful treatment of painful synchondrosis of bipartite patella after direct trauma by operative fixation: A series of

six cases. Open Orthop J 2017;11:390–6. [CrossRef]

31. Mohammad HR, Bitar S, Laughlin-Symon IM, Henry A, Batra G. Bipartite patella separation with quadriceps tendon avulsion: A rare surgical case. Int J Case Rep Images 2014;5:155–9. [CrossRef]
32. Tonotsuka H, Yamamoto Y. Separation of a bipartite patella combined with quadriceps tendon rupture: A case report. Knee 2008;15:64–7. [CrossRef]
33. Gorva AD, Siddique I, Mohan R. An unusual case of bipartite patella fracture with quadriceps rupture. Eur J Trauma 2006;32:411–3. [CrossRef]
34. Matic GT, Flanigan DC. Efficacy of surgical interventions for a bipartite patella. Orthopedics 2014;37:623–8. [CrossRef]
35. Yamaguchi T, Uezaki N, Sakurai H, Kouzuma T, Sakamoto H, Toshimitsu T, et al. Surgical treatment for painful bipartite patellae. Orthop Traumatol 1990;39:13–8. [CrossRef]
36. Bourne MH, Bianco AJ. Bipartite patella in the adolescent: Results of surgical excision. J Pediatr Orthop 1990;10:69–73. [CrossRef]
37. Ogata K. Painful bipartite patella. A new approach to operative treatment. J Bone Joint Surg Am 1994;76:573–8. [CrossRef]
38. Eberhard P, Manueddu C, Hoffmeyer P, Vasey H. Progressive fragmentation of a bipartite patella: Apropos of a case. [Article in French]. Rev Chir Orthop Reparatrice Appar Mot 1995;81:78–80.
39. Ireland ML, Chang JL. Acute fracture bipartite patella: Case report and literature review. Med Sci Sports Exerc 1995;27:299–302. [CrossRef]
40. Tashiro S, Sugita T, Nakamura S, Kurata Y. Gout tophus in the bipartite patella. Orthopedics 2002;25:1295–6. [CrossRef]
41. Adachi N, Ochi M, Yamaguchi H, Uchio Y, Kuriwaka M. Vastus lateralis release for painful bipartite patella. Arthroscopy 2002;18:404–11. [CrossRef]
42. Tauber M, Matis N, Resch H. Traumatic separation of an uncommon bipartite patella type: A case report. Knee Surg Sports Traumatol Arthrosc 2007;15:83–7. [CrossRef]
43. Thomas AL, Wilson RH, Thompson TL, Thomas D, Wilson T. Quadriceps avulsion through a bipartite patella. Quadriceps avulsion through a bipartite patella. Orthopedics 2007;30:491–2. [CrossRef]
44. Woods GW, O'Connor DP, Elkousy HA. Quadriceps tendon rupture through a superolateral bipartite patella. J Knee Surg 2007;20:293–5. [CrossRef]
45. Yoo JH, Kim EH, Ryu HK. Arthroscopic removal of separated bipartite patella causing snapping knee syndrome. Orthopedics 2008;31:717. [CrossRef]
46. Peek AC, Barry M. Patella fracture in a boy with bilateral inferior pole bipartite patellae. Knee 2012;19:716–8. [CrossRef]
47. Werner S, Durkan M, Jones J, Quilici S, Crawford D. Symptomatic bipartite patella: Three subtypes, three representative cases. J Knee Surg 2013;26 Suppl 1:S72–6. [CrossRef]
48. Vaishya R, Chopra S, Vijay V, Vaish A. Bipartite patella causing knee pain in young adults: A report of 5 cases. J Orthop Surg (Hong Kong) 2015;23:127–30. [CrossRef]
49. Kaas L, van der Werf GJIM. A symptomatic cyst originating from a bipartite patella: A case report. Curr Orthop Prac 2015;26:435–7. [CrossRef]
50. James EW, LaPrade CM, Chahla J, Cinque ME, Kennedy NI, LaPrade RF. Arthroscopic excision of bipartite patella with preservation of lateral retinaculum in an adolescent ice hockey player. Am J Orthop (Belle Mead NJ) 2017;46:135–8.
51. Seguritan RE, Wolfe AR, Mena P, Bibawy J, Bianchi C, Solomon N, et al. Bipartite patella separation and partial quadriceps tendon rupture in the setting of trauma. Radiol Case Rep 2019;14:526–9. [CrossRef]
52. Saleh TM, Abbood SH, Abbas TH. Surgical treatment of the non-frequent common symptomatic patella bipartite. Int J Adv Res Med 2019;1:83–5. [CrossRef]
53. Kavanagh EC, Zoga A, Omar I, Ford S, Schweitzer M, Eustace S. MRI findings in bipartite patella. Skeletal Radiol 2007;36:209–14. [CrossRef]
54. Ogden JA. Radiology of postnatal skeletal development. Skeletal Radiol 1984;11:246–57. [CrossRef]
55. Ferrari MB, Sanchez A, Sanchez G, Schantz K, Ellera Gomes JL, Provencher MT. Arthroscopic bony resection for treatment of symptomatic bipartite patella. Arthrosc Tech 2017;6:e1003–7. [CrossRef]
56. Loewen A, Ge SM, Marwan Y, Burman M, Martineau PA. Arthroscopic management for bipartite patella: A systematic review. Orthop J Sports Med 2021;9:23259671211022250. [CrossRef]

STArt
Sports Traumatology & Arthroscopy
DOI: 10.14744/start.2024.75397
Sports Traumatol Arthrosc 2024;1(1):43-48

Review

How to Avoid Iatrogenic Saphenous Nerve Injuries during Hamstring Tendon Harvesting: A Narrative Review

Izzet Bingol,[1] Aliekber Yapar,[2] Enejd Veizi,[1] Haci Ali Olcar,[3] Mehmet Faruk Catma,[4] Oguzhan Pekince,[5] Muhammet Baybars Ataoglu[6]

[1]Department of Orthopaedics and Traumatology, Ankara Yildirim Beyazit University, Ankara, Türkiye

[2]Department of Orthopedics and Traumatology, University of Health Sciences, Antalya Training and Research Hospital, Antalya, Türkiye

[3]Department of Orthopaedics and Traumatology, Yozgat Bozok University Faculty of Medicine, Yozgat, Türkiye

[4]Department of Orthopedics and Traumatology, University of Health Sciences, Ankara Etlik City Hospital, Ankara, Türkiye

[5]Department of Orthopedics and Traumatology, University of Health Sciences, Konya City Hospital, Konya, Türkiye

[6]Department of Orthopedics and Traumatology, Gazi University Faculty of Medicine, Ankara, Türkiye

Cite this article as:
Bingol I, Yapar A, Veizi E, Olcar HA, Catma MF, Pekince O, et al. How to Avoid Iatrogenic Saphenous Nerve Injuries during Hamstring Tendon Harvesting: A Narrative Review. Sports Traumatol Arthrosc 2024;1(1):43-48.

Address for correspondence:
Aliekber Yapar.
Department of Orthopedics and Traumatology, University of Health Sciences, Antalya Training and Research Hospital, Antalya, Türkiye
E-mail:
aliekberyapar@hotmail.com

Submitted: 04.07.2024
Revised: 23.10.2024
Accepted: 24.10.2024
Available Online: 28.11.2024

Sports Traumatology & Arthroscopy – Available online at www.stajournal.com

This work is licensed under a Creative Commons Attribution-NonCommercial 4.0 International License.

ABSTRACT

Anterior cruciate ligament (ACL) reconstruction commonly involves the use of hamstring tendon grafts, which are associated with a risk of saphenous nerve injury, particularly the infrapatellar branch. These injuries can lead to sensory disturbances, including numbness, dysesthesia, and chronic pain, significantly impacting patient outcomes. With the growing use of minimally invasive techniques, understanding how to avoid iatrogenic saphenous nerve injuries during tendon harvesting is critical for optimizing surgical success. This narrative review aims to summarize the current techniques for minimizing saphenous nerve injuries during hamstring tendon harvesting and provide practical recommendations based on existing literature. The review explores various surgical approaches, including different incision placements, tendon harvesting techniques, and innovative minimally invasive methods. Studies were selected based on their focus on reducing nerve injuries, with special emphasis on randomized controlled trials, technical notes, and case series. Techniques such as oblique and modified oblique incisions, posterior mini-incisions, and endoscopic harvesting have demonstrated reduced rates of saphenous nerve injury compared to traditional vertical or transverse incisions. Posterior and popliteal fossa approaches, in particular, showed a significant decrease in injury rates, while endoscopic harvesting further minimizes soft tissue damage. However, limitations include anatomical variability and the technical difficulty of some approaches. To minimize the risk of iatrogenic saphenous nerve injury during hamstring tendon harvesting, surgeons should consider using oblique or posterior incisions, opt for minimally invasive or endoscopic techniques when possible, and tailor their approach to the patient's anatomy. Further research into nerve mapping and long-term outcomes of these methods is needed to refine current practices.

Keywords: ACL reconstruction, hamstring tendon harvesting, iatrogenic injury, nerve protection, saphenous nerve injury

INTRODUCTION

The use of hamstring tendons (HT) as grafts in anterior cruciate ligament (ACL) reconstruction is a well-established and widely accepted surgical technique [1]. However, harvesting HT is not without complications, particularly concerning the saphenous nerve (SN). Iatrogenic injury to the SN, especially its distal branches, including the infrapatellar (IPBSN) and sartorial (SBSN) branches, is common and often results in sensory disturbances, such as hypoesthesia, dysesthesia, and painful neuromas in the affected area [2-4]. These complications can significantly impact patient satisfaction and may even affect postoperative functional outcomes [5-7].

The SN, which runs parallel to the femoral vein and enters the adductor canal before dividing into the infrapatellar (IPBSN) and sartorial (SBSN) branches, is highly susceptible to damage during HT harvesting due to its close proximity to the surgical field [8-10]. Injury to these branches can result from various incision techniques and also instruments used in graft harvesting. Evidence indicates that vertical incisions carry a higher risk of SN injury compared to oblique or horizontal incisions [11,12]. Consequently, sensory disturbances following SN injury are common, with reported rates ranging from 12% to 88%, depending on the incision technique employed [3,11].

Over time, various technical modifications have been proposed to reduce the risk of iatrogenic saphenous nerve (SN) injuries. These modifications include smaller, oblique incisions, alternative incision locations, and minimally invasive endoscopic techniques aimed at preserving nerve integrity [5,12-14]. This review examines the current literature on methods to prevent SN injury during HT harvesting. By exploring these approaches, this review provides a comprehensive overview of the strategies developed to minimize complications associated with HT harvesting, ultimately enhancing postoperative outcomes in anterior cruciate ligament reconstruction (ACLR).

Anatomy of the Saphenous Nerve

Description of the Nerve's Course

The SN represents the longest purely sensory branch of the femoral nerve (Fig. 1). It has its origin in the femoral triangle and runs in close proximity to the femoral artery within the adductor canal before diverging distally [15,16]. The saphenous nerve, which emerges from the adductor canal, subsequently divides into two principal branches: the SBSN and the IPBSN. The IPBSN typically traverses medially, running superficial to the sartorius muscle, and courses down the medial aspect of the knee. It provides sensory innervation to the anteromedial aspect of the knee and the anteroinferior portion of the knee joint [17,18]. The IPBSN frequently crosses the patellar tendon in a transverse manner, with the trajectory depending on the

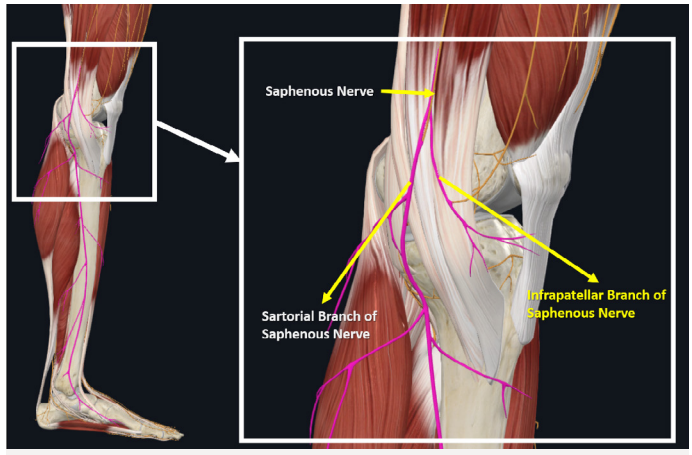

Figure 1. The anatomy of the saphenous nerve and its branches.

presence of anatomical variability. In the medial aspect, the course is nearly vertical, whereas at the level of the patellar tendon, it is oblique [10,17]. The SBSN runs in a more posterior direction, descending alongside the sartorius muscle and gracilis tendon. It emerges subcutaneously in the vicinity of the medial malleolus and provides sensation to the medial aspect of the leg and foot [16,19,20].

Vulnerable Zones

Several regions of the saphenous nerve and its branches are particularly vulnerable during surgical interventions involving HT harvesting. The IPBSN is at significant risk due to its proximity to the graft harvesting site. This branch typically pierces or courses along the sartorius muscle, and because of its superficial location near the medial knee, it is prone to injury during tendon stripping or incisions [17,20]. Anatomical studies indicate that the IPBSN is highly variable, with the nerve trunk located between 4 and 7 mm from the medial border of the patella [18,19]. The region where the SN exits the adductor canal and the sub-sartorial space, located just above the tibiofemoral joint line, is another vulnerable area. Injuries in this region often occur during blunt dissection or tendon strippers are used [20]. Cadaveric studies have demonstrated that gracilis tendon harvesting can lead to both incisional and non-incisional injuries, with non-incisional injuries affecting the sartorial branch as it descends posteriorly to the medial hamstring tendons [20]. Moreover, the course of the nerve varies significantly, making it challenging to define a "safe zone" during graft harvesting procedures [10]. As a conclusion, SN, particularly its IPBSN, is at high risk for iatrogenic injury during HT harvesting due to its anatomical course along the medial aspect of the knee. Knowledge of the nerve's trajectory and its anatomical variability is essential for surgeons to minimize the risk of sensory disturbances.

Clinical Presentation following SN injury

Injury to the SN can lead to several clinical manifestations, ranging from mild sensory disturbances to debilitating neuropathic pain. The most common symptom following a saphenous nerve injury is numbness or hypoesthesia along the medial aspect of the knee and leg. Patients typically describe a "dead" or "numb" feeling in the affected area, with diminished sensitivity to touch [3,4]. This sensory loss may extend to the medial lower leg, depending on the extent of the injury. In some cases, patients may experience sharp, shooting pains in the distribution of the injured nerve. Neuropathic pain can be persistent and may be exacerbated by movement or touch, making it a significant source of postoperative discomfort [12]. Dysesthesia, or abnormal sensations, such as tingling or burning, is another common symptom. Some patients may develop allodynia, where even light touch causes significant pain [21]. These symptoms can interfere with daily activities and affect the patient's overall quality of life. Rarely, injury to the nerve can lead to the formation of neuromas, which are painful nerve growths. Neuromas are particularly troublesome, as they often result in chronic pain and may require additional interventions such as nerve block injections or even surgical excision [3]. Patients with significant saphenous nerve injuries often report prolonged recovery periods, with persistent sensory deficits lasting months or even years after surgery. In some cases, these symptoms may be permanent [4,12]. A recent study has demonstrated that patients with SN injury have a higher incidence of re-rupture compared to those without [7].

Preventative Techniques

Minimizing trauma to the saphenous nerve (SN) during tendon harvesting requires careful attention to surgical technique. Several approaches have been developed to mitigate the risk of nerve injury (Table 1).

Incision Placement

Optimal incision placement is essential to reduce the risk of SN injury during hamstring tendon (HT) harvesting. Various incision types—including vertical, oblique, popliteal, and transverse—have been evaluated for their impact on the infrapatellar branch of the saphenous nerve (IPBSN) and other branches. Studies have consistently demonstrated that oblique incisions are superior to vertical and transverse incisions in reducing nerve damage risk [6,9,11,12,22]. Zhu et al. [12] compared a modified oblique incision with the classic oblique incision, showing a significant reduction in IPBSN injuries (9.4% vs. 33.3%). Oblique incisions are recommended due to their alignment with Langer's lines, which minimizes sensory disturbances [12,22]. Additional techniques, such as the posterior mini-incision in the popliteal fossa, described by Kodkani et al. and Prodromos et al., have been successful in avoiding SN injury altogether [2,14]. In a prospective randomized trial, Franz and Baumann found that a popliteal fossa incision led to no nerve injuries, while a conventional anteromedial incision had a 14% injury rate [8]. Similarly, García Hernández et al. [21] reported only a 2% incidence of sensory complications with the posterior approach, compared to 16% with the anterior approach.

Table 1. Hamstring tendon harvesting techniques that might decrease iatrogenic SN injuries

Author	Year	Study design	Technique	SN injury
Kodkani et al. [2]	2004	Technical note	Posteromedial incision	Not reported
Prodromos et al. [14]	2005	Case series (n=175)	Popliteal incision	%0
Mirzatolooei and Pisoodeh [3]	2012	Prospective comparison (n=98)	Surgical exploration and detection of the SN branches	20.5% versus 72%
de Padua et al. [4]	2015	Retrospective comparison (n=110)	Single ST tendon harvesting vs. ST & GT harvesting	36.1% vs. 58.1%
Franz and Baumann [8]	2016	Randomized clinical trial (n=100)	Popliteal fossa incision vs. Classical anteromedial oblique incision	0% versus 14%
Colombet and Graveleau [5]	2016	Technical note	Endoscopic	Not reported
Yeh et al. [13]	2018	Technical note	Endoscopic	Not reported
Zhu et al. [12]	2021	Randomized clinical trial (n=62)	Posterior modified oblique incision vs. Classical anteromedial oblique incision	9.4% vs. 33.3%
García Hernández et al. [21]	2022	Retrospective comparison (n=100)	Popliteal fossa incision vs. Classical anteromedial oblique incision	2% vs. 16%

Tendon Harvesting Techniques

Minimally invasive techniques, such as the anterior semitendinosus harvest described by Colombet and Graveleau, aim to reduce incision size and limit soft tissue disruption [5]. This approach uses a 2 cm incision with precise tendon identification, decreasing the likelihood of inadvertent nerve injury [5]. Yeh et al. [13] introduced an endoscopic harvesting technique that requires a smaller incision (1-1.5 cm) and provides better visualization, allowing for safer dissection of fascial bands and accessory tendons. This technique enables clear identification of the gracilis and semitendinosus tendons, reducing the risk of SN injury by maintaining a controlled and well-visualized dissection. Direct visualization of the saphenous nerve branches may be advantageous for cases with a particularly high risk of nerve injury. Mirzatolooei and Pisoodeh [3] demonstrated that by exploring and protecting sensory branches of the SN during harvesting, the rate of postoperative sensory loss was reduced from 72% to 20.5%. By carefully selecting incision sites and employing advanced harvesting techniques, surgeons can significantly decrease the risk of iatrogenic SN injuries during HT harvesting.

DISCUSSION

The findings from this review highlight several techniques designed to reduce the incidence of SN injuries during HT harvesting. The effectiveness of oblique incisions in reducing IPBSN injuries has been consistently demonstrated. Zhu et al. [12] reported that a modified oblique incision significantly lowered the risk of IPBSN injury compared to the classic oblique incision (9.4% vs. 33.3%). Similarly, Mirzatolooei and Pisoodeh found that direct visualization and preservation of saphenous nerve branches during surgery reduced postoperative sensory deficits from 72% to 20.5% [3]. Posterior incision techniques, such as those proposed by Kodkani et al. [2] and Prodromos et al. [14], showed promising results in reducing nerve injuries. Franz and Baumann found that harvesting the hamstring tendon via a popliteal fossa incision eliminated nerve injuries compared to the conventional anteromedial approach (0% vs. 14%) [8]. These findings align with García Hernández et al. [21], who reported a lower rate of neurological complications (2%) with the posterior approach. However, evidence remains scarce on the long-term sensory outcomes of some techniques, particularly minimally invasive and endoscopic harvesting approaches. While studies such as those by Colombet and Graveleau [5] and Yeh et al. [13] have introduced innovative methods with smaller incisions, the long-term sensory outcomes of these techniques have not been fully explored.

Although several harvesting techniques have been developed to reduce SN injury, each has limitations. The primary limitation of posterior and minimally invasive approaches is the risk of a shorter tendon harvest. Franz and Baumann found that while the posterior approach reduced nerve injuries, it also resulted in a slightly shorter tendon length (272 mm vs. 292 mm with the anteromedial approach), which may affect graft strength and sufficiency for fixation [8]. Similarly, Yeh et al. [13] noted that the endoscopic technique, while reducing incision size, requires advanced skills and specialized equipment, potentially limiting its widespread adoption. Another limitation is the SN's anatomical variability. Even with meticulous surgical techniques, variations in nerve anatomy may increase the likelihood of nerve injury.

Future studies should focus on refining existing techniques and exploring novel approaches to reduce the incidence of SN injuries further. Potential research areas might include refinement of endoscopic graft harvesting, nerve mapping technologies, and comparative studies on different techniques. In the future, endoscopic hamstring tendon harvesting can replace traditional open surgical techniques. Integrating intraoperative nerve monitoring or mapping technologies could provide surgeons with real-time feedback, helping them avoid nerve injury during tendon harvesting. Large-scale, multi-center trials comparing the sensory outcomes of posterior, oblique, and endoscopic approaches over extended follow-up periods are needed to confirm which method offers the best balance between tendon harvest quality and nerve safety.

CONCLUSIONS AND CLINICAL RECOMMENDATIONS

Preventing iatrogenic SN injuries during HT harvesting remains critical in anterior cruciate ligament (ACL) reconstruction. Various techniques, such as modified oblique incisions, posterior approaches, and endoscopic harvesting, have shown promise in reducing the incidence of nerve injuries. Studies comparing incision types and surgical methods have consistently found that posterior and minimally invasive techniques result in fewer nerve injuries than traditional anteromedial approaches. However, challenges such as tendon shortening and anatomical variability remain. Based on the findings of this review, the following practical recommendations are suggested for surgeons to minimize the risk of saphenous nerve injuries. To minimize the risk of nerve injury during hamstring tendon harvesting, surgeons should prioritize specific strategies to improve patient outcomes. An oblique or posterior incision is recommended whenever feasible, as these approaches have been demonstrated to reduce the likelihood of nerve injury. Additionally, minimizing

incision size by considering minimally invasive or endoscopic techniques can further decrease soft tissue trauma and nerve damage. Although these techniques require advanced training and specialized equipment, their benefits in reducing complications are notable. In cases with a heightened risk of nerve injury, it is advisable to visualize and preserve saphenous nerve branches intraoperatively. By carefully exploring and identifying these branches, surgeons can help prevent postoperative sensory loss in patients. Furthermore, as the anatomy of the saphenous nerve can vary significantly, tailoring surgical techniques to each patient's unique anatomical structure is essential. Thorough preoperative planning should include a detailed assessment of individual anatomical variations, enabling adjustments in the approach as necessary.

DECLARATIONS

Acknowledgments: Turkish Sports Traumatology Arthroscopy and Knee Surgery Society, ACL Study Group members prepared this narrative review. The authors would like to express their gratitude to all contributors for their valuable input and expertise throughout the development of this review.

Ethics Committee Aproval: Not applicable.

Author Contributions: Idea/Concept – IB, AY, EV; Design – HAO, FC, OP, MBA; Control/Supervision – IB, MBA, AY; Data Collection and/or Processing – FC, OP; Analysis and/or Interpretation – AY, HAO; Literature review – IB, EV, MBA; Writing – IB, AY, EV, OP; Critical Review – IB, MBA, FC; References and fundings – AY, OP, EV; Materials – HAO, FC.

Data Avaliability Statement: The data that support the findings of this study are available from the corresponding author upon reasonable request.

Conflict of Interest: The authors declared that they have no competing interests.

Informed Consent: Not applicable.

Use of AI for Writing Assistance: The authors declared that they had not used any type of generative artificial intelligence for the writing of this manuscript, nor for the creation of images, graphics, tables, or their corresponding captions.

Financial Disclosure: The author declares that they have no relevant or material financial interests that relate to the research described in this paper.

Funding Disclosure: No specific funding was received to prepare this manuscript.

Peer-review: Externally peer-reviewed.

ABBREVIATIONS

ACL: Anterior Cruciate Ligament

COI: Classic Oblique Incision

MOI: Modified Oblique Incision

IPBSN: Infrapatellar Branch of the Saphenous Nerve

SN: Saphenous Nerve

HT: Hamstring Tendon

REFERENCES

1. Baawa-Ameyaw J, Plastow R, Begum FA, Kayani B, Jeddy H, Haddad F. Current concepts in graft selection for anterior cruciate ligament reconstruction. EFORT Open Rev 2021;6:808–15. [CrossRef]
2. Kodkani PS, Govekar DP, Patankar HS. A new technique of graft harvest for anterior cruciate ligament reconstruction with quadruple semitendinosus tendon autograft. Arthroscopy 2004;20:e101–4. [CrossRef]
3. Mirzatolooei F, Pisoodeh K. Impact of exploration of sensory branches of saphenous nerve in anterior cruciate ligament reconstructive surgery. Arch Iran Med 2012;15:219–22.
4. de Padua VB, Nascimento PE, Silva SC, de Gusmão Canuto SM, Zuppi GN, de Carvalho SM. Saphenous nerve injury during harvesting of one or two hamstring tendons for anterior cruciate ligament reconstruction. Rev Bras Ortop 2015;50:546–9. [CrossRef]
5. Colombet P, Graveleau N. Minimally invasive anterior semitendinosus harvest: A technique to decrease saphenous nerve injury. Arthrosc Tech 2016;5:e139–42. [CrossRef]
6. Ruffilli A, De Fine M, Traina F, Pilla F, Fenga D, Faldini C. Saphenous nerve injury during hamstring tendons harvest: Does the incision matter? A systematic review. Knee Surg Sports Traumatol Arthrosc 2017;25:3140–5. [CrossRef]
7. Egerci OF, Dogruoz F, Asoglu MM, Ertan MB, Yapar A, Kose O. The prognosis of iatrogenic saphenous nerve injuries during hamstring tendon harvesting in anterior cruciate ligament reconstruction. J Orthop Surg Res 2024;19:428. [CrossRef]
8. Franz W, Baumann A. Minimally invasive semitendinosus tendon harvesting from the popliteal fossa versus conventional hamstring tendon harvesting for ACL reconstruction: A prospective, randomised controlled trial in 100 patients. Knee 2016;23:106–10. [CrossRef]
9. Pękala PA, Tomaszewski KA, Henry BM, Ramakrishnan PK, Roy J, Mizia E, et al. Risk of iatrogenic injury to the infrapatellar branch of the saphenous nerve during hamstring tendon harvesting: A meta-analysis. Muscle Nerve 2017;56:930–7. [CrossRef]

10. Patterson DC, Cirino CM, Gladstone JN. No safe zone: The anatomy of the saphenous nerve and its posteromedial branches. Knee 2019;26:660–5. [CrossRef]
11. Grassi A, Perdisa F, Samuelsson K, Svantesson E, Romagnoli M, Raggi F, et al. Association between incision technique for hamstring tendon harvest in anterior cruciate ligament reconstruction and the risk of injury to the infra-patellar branch of the saphenous nerve: A meta-analysis. Knee Surg Sports Traumatol Arthrosc 2018;26:2410–23. [CrossRef]
12. Zhu B, Li X, Lou T. A modified oblique incision in hamstring tendon graft harvesting during ACL reconstruction. J Orthop Surg Res 2021;16:206. [CrossRef]
13. Yeh WL, Chen JM, Liu CH, Tsai PJ, Higashiyama R, Takaso M. Endoscopic harvest of autogenous gracilis and semitendinosus tendons. Arthrosc Tech 2018;7:e1019–24. [CrossRef]
14. Prodromos CC, Han YS, Keller BL, Bolyard RJ. Posterior mini-incision technique for hamstring anterior cruciate ligament reconstruction graft harvest. Arthroscopy 2005;21:130–7. [CrossRef]
15. Mochizuki T, Akita K, Muneta T, Sato T. Anatomical bases for minimizing sensory disturbance after arthroscopically-assisted anterior cruciate ligament reconstruction using medial hamstring tendons. Surg Radiol Anat 2003;25:192–9. [CrossRef]
16. Im JH, Lee JY, Yeon WH, Lee MK, Chung YG. The anatomy of the saphenous and sural nerves as a source of processed nerve allografts. Cell Tissue Bank 2020;21:547–55. [CrossRef]
17. Kerver AL, Leliveld MS, den Hartog D, Verhofstad MH, Kleinrensink GJ. The surgical anatomy of the infrapatellar branch of the saphenous nerve in relation to incisions for anteromedial knee surgery. J Bone Joint Surg Am 2013;95:2119–25. [CrossRef]
18. Kalthur SG, Sumalatha S, Nair N, Pandey AK, Sequeria S, Shobha L. Anatomic study of infrapatellar branch of saphenous nerve in male cadavers. Ir J Med Sci 2015;184:201–6. [CrossRef]
19. Dayan V, Cura L, Cubas S, Carriquiry G. Surgical anatomy of the saphenous nerve. Ann Thorac Surg 2008;85:896–900. [CrossRef]
20. Wisbech Vange S, Tranum-Jensen J, Krogsgaard MR. Gracilis tendon harvest may lead to both incisional and non-incisional saphenous nerve injuries. Knee Surg Sports Traumatol Arthrosc 2020;28:969–74. [CrossRef]
21. García Hernández JM, López-Vidriero Tejedor E, Castañeda González S, Yrayzoz Fuentes J, Periáñez Moreno R, Saval Benítez JM, et al. Posterior hamstring harvest improves aesthetic satisfaction and decreases sensory complications as compared to the classic anterior approach in anterior cruciate ligament reconstruction surgery. J Exp Orthop 2022;9:109. [CrossRef]
22. Hardy A, Casabianca L, Andrieu K, Baverel L, Noailles T; Junior French Arthroscopy Society. Complications following harvesting of patellar tendon or hamstring tendon grafts for anterior cruciate ligament reconstruction: Systematic review of literature. Orthop Traumatol Surg Res 2017;103:S245–8. [CrossRef]