

Original Article

Knees With Severe Varus Deformities End Up With More Oblique Joint Lines After Total Knee Arthroplasty

 Elcil Kaya Bicer,  Murat Celal Sozbilen,  Hakki Sur,  Semih Aydogdu

Department of Orthopedics and Traumatology, Ege University Faculty of Medicine, Izmir, Türkiye

ABSTRACT

Objective: Achieving optimal mechanical alignment and precise component positioning is critical for the success of total knee arthroplasty (TKA). It is also essential to consider the orientation of the joint line, particularly in relation to the ground, in the postoperative period. This study aimed to evaluate the postoperative knee joint line orientation in patients with severe preoperative varus deformities compared to those with mild to moderate deformities.

Materials and Methods: This retrospective study included 60 knees from 59 patients, divided into two groups: 30 knees with mild to moderate varus deformities (mechanical axis deviations $<20^\circ$, Group 1) and 30 knees with severe varus deformities (mechanical axis deviations $\geq 20^\circ$, Group 2). A comparison was made between the preoperative and postoperative radiographs to analyze the mechanical axes, femoral and tibial component positioning, and joint line orientation in relation to the ground.

Results: The preoperative mean mechanical axis deviations were $11.13^\circ \pm 4.07^\circ$ in Group 1 and $22.60^\circ \pm 2.24^\circ$ in Group 2. While femoral and tibial component positioning did not significantly differ between the groups, joint line orientation relative to the floor showed significant differences. The mean tibial component inclination was $4.73^\circ \pm 2.58^\circ$ in Group 2, compared to $3.07^\circ \pm 1.77^\circ$ in Group 1 ($p=0.005$). Similarly, the mean femoral component inclination was $5.24^\circ \pm 2.36^\circ$ in Group 2 and $3.69^\circ \pm 1.87^\circ$ in Group 1 ($p=0.007$). In knees with severe varus deformities, joint line obliquity was significantly greater postoperatively.

Conclusion: Routine instrumentation for TKA is less reliable in severely deformed knees due to soft tissue contractures and the need for extensive release procedures. Severe varus deformities result in the inclination of components being more lateral and an increased obliquity of the joint line following mechanically aligned TKA. Further research is necessary to determine the long-term impact of this lateral inclination on prosthesis survival and clinical outcomes.

Keywords: Joint line obliquity, joint line orientation, severe varus deformity, total knee arthroplasty



Cite this article as:

Kaya Bicer E, Sozbilen MC, Sur H, Aydogdu S. Knees With Severe Varus Deformities End Up With More Oblique Joint Lines After Total Knee Arthroplasty. Sports Traumatol Arthrosc 2025;2(1):4–10.

Address for correspondence:

Elcil Kaya Bicer,
Department of Orthopedics and Traumatology, Ege University Faculty of Medicine, Izmir, Türkiye
E-mail: elcil@yahoo.com

Submitted: 11.10.2024

Revised: 18.11.2024

Accepted: 18.11.2024

Available Online: 10.03.2025

Sports Traumatology & Arthroscopy – Available online at www.stajournal.com



This work is licensed under a Creative Commons Attribution-NonCommercial 4.0 International License.

INTRODUCTION

The alignment of the lower limb in the coronal plane and the orientation of the joint line are critical factors in both the onset and progression of knee osteoarthritis, as well as the success of total knee arthroplasty (TKA) [1,2]. Evaluating the joint line orientation relative to the floor is a key method for assessing knee alignment and implant positioning. Its significance lies in its direct biomechanical impact, particularly in terms of shear stress and load distribution [3-5].

Parameters of knee joint orientation, such as joint line tilt, are essential in preventing component malposition during TKA or secondary realignment surgeries. Misalignment of the knee joint line can influence the extent of bone resection at the distal femur and proximal tibia. When joint line obliquity is used as the sole reference for axial alignment at the femoral posterior condyle, it can affect the rotation of the femoral components, leading to suboptimal outcomes [1,2,6].

Correcting severe varus deformities during TKA can be particularly challenging in cases involving medial compartment bone loss, a significantly contracted medial collateral ligament, or lateral structure laxity [7]. Consequently, achieving optimal joint line orientation and alignment in knees with severe varus deformities may be technically more demanding than in knees with milder deformities [8].

Restoration of the knee joint line orientation is widely considered an essential factor in successful knee arthroplasty. Postoperatively, patients with minimal deviation from a parallel joint line orientation tend to achieve the best functional outcomes, including greater range of motion, reduced patellofemoral pain, and fewer mechanical complications [1].

This study evaluated and compared component positioning and joint line orientation in TKA patients with severe varus deformities and those with mild to moderate varus deformities. We hypothesized that restoring coronal plane alignment of the limb does not necessarily guarantee optimal joint line orientation. Even if the components are implanted perpendicularly relative to the mechanical axis, achieving a parallel joint line orientation with the floor may not be assured.

MATERIALS AND METHODS

Patients and Study Design

This study protocol was approved by the institutional ethics committee (Approval Date/Issue: 24.06.2014, 14-4.2/12). A total of 60 knees from 59 patients (mean age: 70.40±7.73 years) who underwent total knee arthroplasty (TKA) between November 2005 and February 2014 were included in this retrospective study. The patients were randomly selected from those who had undergone TKA; only those with available preoperative

and postoperative long-leg radiographs were included. The patients were categorized into two groups based on their preoperative mechanical axis deviations: Group 1 consisted of patients with mild to moderate varus deformities (<20°), while Group 2 comprised patients with severe varus deformities (≥20°) (Table 1). Each group included 30 knees. The mean follow-up duration was 32.35±25.91 months. The etiology was primary osteoarthritis in 54 patients and rheumatoid arthritis in six. None of the patients had a history of prior surgery. The demographic characteristics of the patients are summarized in Table 1. This study was conducted in accordance with the STROBE guidelines.

Surgical Technique

All surgeries were performed by the two senior authors (S.A. and H.S.) under regional epidural anesthesia. The standard medial parapatellar or subvastus approaches were employed for each procedure. Intramedullary instrumentation was used for both the femoral and tibial sides, and hybrid or cemented posterior cruciate ligament-retaining total knee arthroplasties (TKAs) were performed. In the severe deformity group, five knees received extension stems on the tibial side. An all-polyethylene component was used on the patellar side for all patients. Both surgeons adhered to a predefined, standardized surgical protocol for all procedures, encompassing detailed preoperative planning and uniform intraoperative steps for implant positioning and soft tissue management.

Radiological Measurements

Preoperative and postoperative knee radiographs were obtained using standing weight-bearing long-leg anteroposterior radiographs and standard anteroposterior and lateral short knee radiographs. The standing long-leg

Table 1. Patient characteristics and preoperative mechanical axis deviations

	Group 1 <20° varus (n=30)	Group 2 ≥20° varus (n=30)
Mechanical Axes	11.13°±4.06°	22.60°±2.24°
Age (years) (Mean±SD)	70.63±7.92 (53–82)	70.17±7.67 (53–83)
Sex	3♂ 27♀	3♂ 27♀
Side (right/left)	13 R 17 L	18 R 12 L
Postoperative duration (months)	36.57±30.44	28.13±20.09
Surgical approach	Subvastus 12 Standard 18	Subvastus 15 Standard 15

radiographs (hip to ankle) were taken unassisted, with the patient standing bipedally in knee extension and the lateral malleoli positioned 20 cm apart. The patient's feet were elevated 5 cm to visualize the ankle joints. To avoid malrotation, the patella was aligned perpendicular to the x-ray source. A digital radiography system (Ysio Max, Siemens, Erlangen, Germany) was used with a focus-to-detector distance of 3 m. Lateral short knee radiographs were taken with the patient in the lateral decubitus position on the operative side, with the knee flexed 20–30° and the contralateral knee fully extended. The patella and epicondyle were positioned perpendicular to the cassette to prevent rotation. The X-ray source was centered at a distance of 100 cm from the medial femoral epicondyle^[9,10]. Digital measurements were made using a picture archiving and communication system (syngo; Siemens, Erlangen, Germany), and all patients underwent the same radiographic examination.

Femoral and tibial component positioning on short-leg radiographs was assessed in both the frontal and sagittal planes using the American Knee Society Radiographic Evaluation System^[11]. Postoperative mechanical axis deviations and component positioning relative to the femoral and tibial mechanical axes were assessed using standing anteroposterior radiographs^[9,12]. Component positioning was then compared between the two groups (Figs. 1 and 2). The posterior tibial slope angle was measured preoperatively on lateral radiographs as the angle between the proximal mid-diaphyseal anatomical line and the line parallel to the tibial plateau.

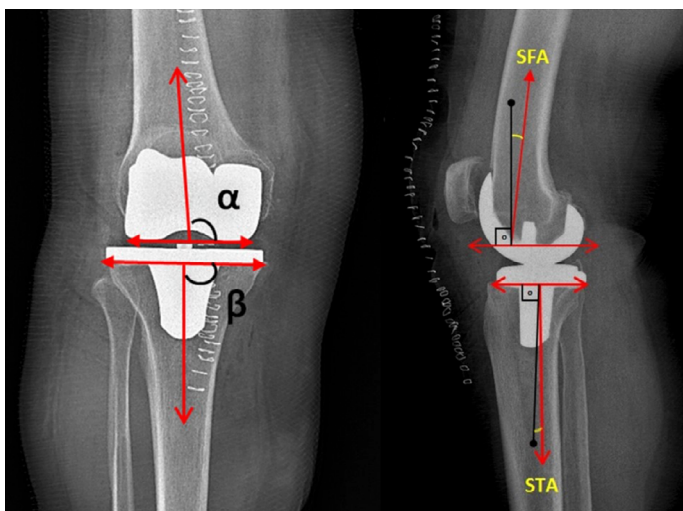


Figure 1. Measurements of the frontal and sagittal femoral and tibial component angles (α , β , SFA, and STA) on short knee radiographs.

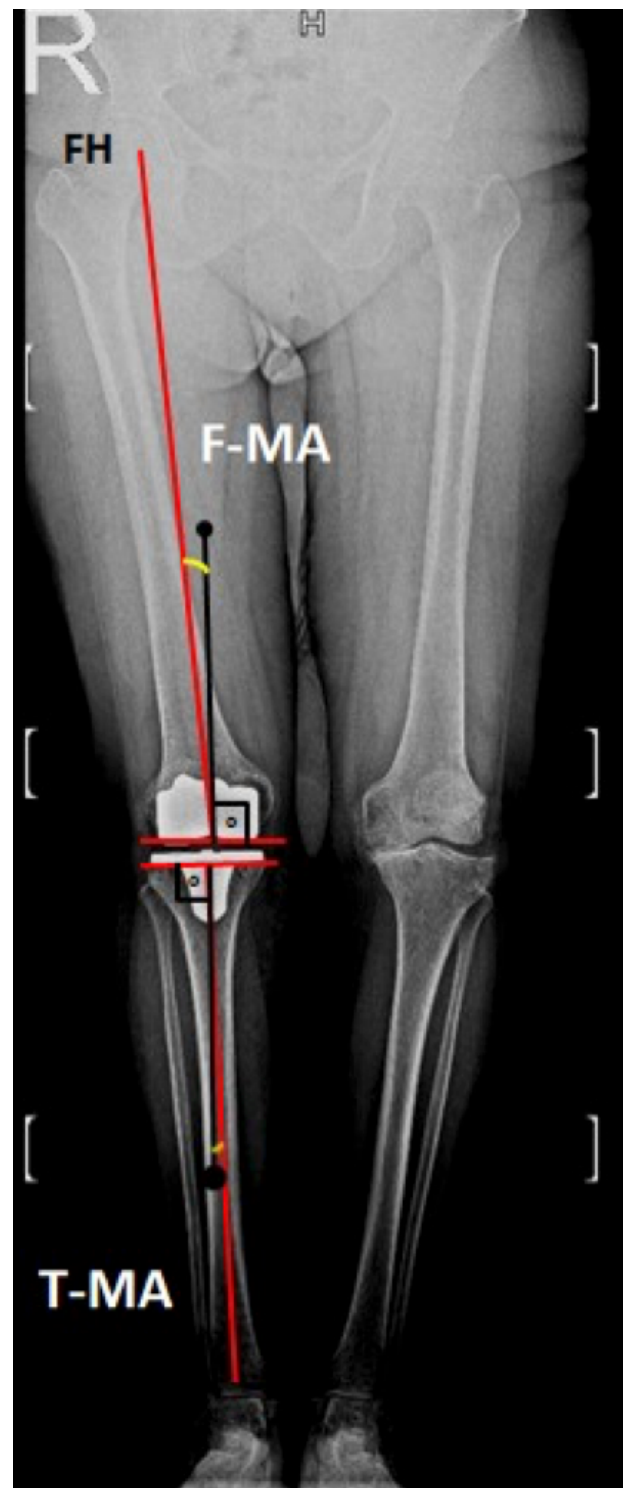


Figure 2. Postoperative measurements of the mechanical axis deviations and component positioning relative to the mechanical axes of the femur and tibia.

F-MA (femoral mechanical axis and femoral component), T-MA (tibial mechanical axis and tibial component).

On the short knee radiographs, the normal component positioning values were as follows: frontal femoral component angle (α angle)= 92° – 98° , frontal tibial component angle (β angle)= 90° , sagittal femoral angle (SFA) $\leq 3^{\circ}$ of flexion, and sagittal tibial angle (STA)= 0° – 7° posterior slope. Angles outside of these values were considered outliers, and the proportion of outliers was compared between the two groups.

Component orientation was further assessed by measuring the inclinations of the femoral and tibial components relative to the ground and by calculating the angles between tangential lines drawn parallel to the femoral and tibial components (tibiofemoral angle, TFA) on postoperative standing long-leg anteroposterior radiographs^[1,13,14]. The F angle was defined as the angle between the tangential line drawn parallel to the most prominent parts of the medial and lateral condyles of the femoral component and the line parallel to the ground. Similarly, the T-angle was defined as the angle between the tangential line drawn parallel to the tibial baseplate and the line parallel to the ground (Fig. 3).

Statistical Analysis

Statistical analyses were performed using the Statistical Package for the Social Sciences, version 18 (SPSS Inc., Chicago,

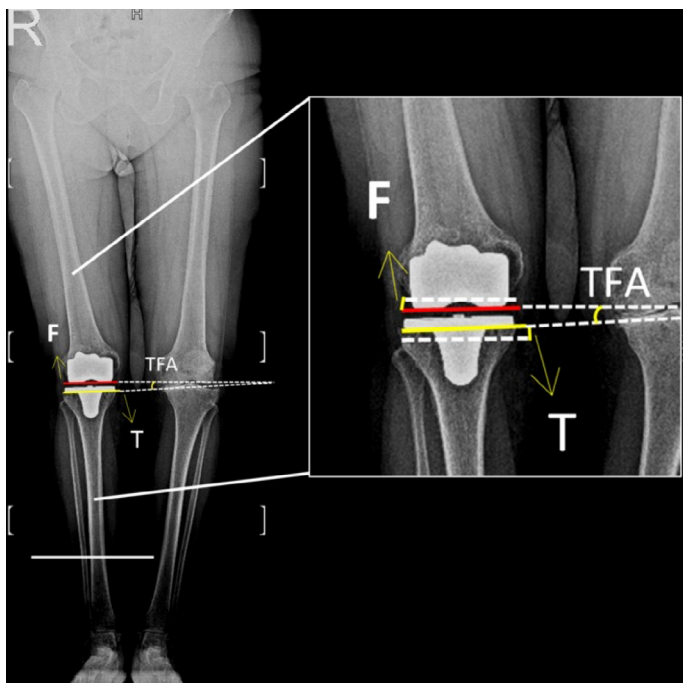


Figure 3. Evaluation of component orientation, including the inclination angles of the femoral and tibial components relative to the floor and the tibiofemoral angle (TFA), measured on postoperative standing long-leg anteroposterior radiographs.

IL, USA). Descriptive statistics were presented as means, standard deviations, and percentages. The normality of distribution was tested using the one-sample Kolmogorov-Smirnov test, and the homogeneity of variances was determined using the Levene test. Independent t-tests were used to compare means, and Fisher's exact test was used to compare proportions. The significance level was set at 0.05.

RESULTS

The mean preoperative mechanical axis deviations were $11.13^{\circ} \pm 4.06^{\circ}$ (range, 2° – 17°) in the mild to moderate varus deformity group and $22.60^{\circ} \pm 2.24^{\circ}$ (range, 20° – 27°) in the severe deformity group. Component positioning measured on the short knee radiographs showed that the frontal, sagittal femoral and tibial component angles (α , β , SFA, STA) were not significantly different between the mild to moderate and severe deformity groups. The outlier ratios of these four angles were comparable between the two groups (Table 2).

As measured on the long-leg radiographs, the postoperative mechanical axis deviations and the angles between the components and the mechanical axes of the femur and tibia did not exhibit statistically significant differences between the groups (Table 3).

The radiographic evaluations of the orientations of the components in relation to the ground revealed that both the femoral and tibial components exhibited a significantly greater lateral inclination in the group with severe deformities (Table 2). The mean inclination of the tibial components was $4.73^{\circ} \pm 2.58^{\circ}$ in group 2, in comparison to $3.07^{\circ} \pm 1.77^{\circ}$ in group 1 ($p=0.005$). The mean inclination angle of the femoral components was $5.24^{\circ} \pm 2.36^{\circ}$ in group 2 and $3.69^{\circ} \pm 1.87^{\circ}$ in group 1 ($p=0.007$). It was observed that the joint line obliquity was greater following the TKAs in the highly deformed knees. The comparison of the angles between the component inclinations (TFA) revealed no statistically significant differences between the two groups (Table 2).

DISCUSSION

Total knee arthroplasty presents a distinctive set of challenges in cases where the knees exhibit severe varus deformities. When the sole perioperative focus is restoring the mechanical axis of the lower extremity, this can result in errors in component placement. In addition to addressing various other parameters, the postoperative artificial knee joint line should ideally be parallel to the ground and perpendicular to the weight-bearing axis^[2,15]. Failure in mechanically aligned TKAs has been documented to be higher due to excessive load variations and an increased number of outliers in joint line orientation^[1,16].

Table 2. Inclination of the femoral and tibial components relative to the ground (mean±standard deviation [SD]). Component positioning angles in the frontal and sagittal planes measured on short knee radiographs (mean±SD), including the proportion of outliers

	Group 1 <20° varus (n=30) (Mean±SD)	Group 2 ≥20° varus (n=30) (Mean±SD)	p*
Inclinations of the femoral and tibial components relative to the floor			
Inclination of the tibial component relative to the floor (T)	3.07°±1.77°	4.73°±2.58°	0.005*
Inclination of the femoral component relative to the floor (F)	3.69°±1.87°	5.24°±2.36°	0.007*
Angle between the inclinations of the tibial and femoral components (TFA)	1.02°±0.79°	1.14°±0.72°	0.546
Component positioning in the frontal and sagittal planes as measured on short knee radiographs (mean±SD)			
Posterior tibial slope (preoperative)	6.64°±2.53°	7.98°±3.25°	0.08
Frontal femoral component angle (α angle)	96.32°±2.80°	96.29°±3.09°	0.969
Frontal tibial component angle (β angle)	90.12°±2.49°	90.78°±2.69°	0.317
Sagittal femoral component angle (SFA)	3.24°±2.64°	4.06°±4.00°	0.353
Sagittal tibial component angle (STA)	3.93°±2.13°	3.30°±3.08°	0.358
Component positioning outliers on short knee radiographs n (%)			
Frontal femoral component angle (α angle)	9 (30)	8 (26.7)	1.000
Frontal tibial component angle (β angle)	26 (86.7)	24 (80)	0.731
Sagittal femoral component angle (SFA)	13 (43.3)	16 (53.3)	0.606
Sagittal tibial component angle (STA)	1 (3.3)	6 (20)	0.103

p*: Independent t-test; p**: Fisher’s exact test.

Table 3. Component positioning measured on standing long-leg radiographs, presented in relation to the mechanical axes (Mean±SD)

Angles between	Group 1 <20° varus (n=30)	Group 2 ≥20° varus (n=30)	p
Femoral and tibial mechanical axes	3.93°±2.13°	3.30°±3.08°	0.136
Tibial mechanical axis & tibial component	6.64°±2.53°	7.98°±3.25°	0.779
Femoral mechanical axis & femoral component	92.32°±2.01°	93.19°±3.66°	0.258

The present study demonstrated that, although the components could be accurately implanted in both the frontal and sagittal planes in knees with severe varus deformities (mechanical axis deviation ≥20°), achieving a parallel orientation of the

components with respect to the ground was more challenging compared to knees with milder deformities. The inclination of the components was more oblique in knees with severe deformities than in those with mild deformities. Although postoperative mechanical axis deviations in the severe deformity group were not significantly different from those in the mild to moderate deformity group, restoration was observed to be more optimal in the latter group.

In a successfully implanted, mechanically aligned TKA, even with proper correction of coronal plane alignment, insufficient release of contracted soft tissues can lead to complications in the postoperative outcome. Imbalances in soft tissue may result in discrepancies in the orientation of the knee joint line. The meticulous execution of osteotomies can facilitate the restoration of limb alignment in the coronal plane. However, the presence of minor angular discrepancies, which are often compounded by the imbalance of soft tissues, can considerably impact the outcome [17,18]. As determined by anthropometric studies [2,17], the target inclination of the knee joint line represents the objective in TKA for severely deformed knees.

Nevertheless, attaining this inclination can prove challenging due to the presence of soft tissue contractures.

Another factor that has been linked with postoperative changes in the alignment of the knee joint line is the presence of severe hindfoot deformity. Failure to correct the ankle joint inclination in knees with severe varus deformity following total knee arthroplasty (TKA) can result in an unfavorable alignment of the knee joint, preventing a parallel orientation^[19]. In cases of advanced varus, the pre-existing constitutional varus deformity and joint obliquity are frequently elevated, even in the contralateral, unaffected knee^[20]. Consequently, the anticipated postoperative inclination of the components may be greater than that observed in patients with mild varus deformities. In such cases, it may be more appropriate to target a patient-specific inclination that optimizes functional outcomes rather than striving for values that are expected in the general population or in patients with mild varus deformities.

Nishida et al.^[21] reported excellent functional outcomes in patients with both mild residual varus deformities and neutral alignment following TKA, with mild varus alignment deemed acceptable. Nevertheless, further clinical trials and functional data, particularly in patients with severe varus deformities, are required to reach definitive conclusions.

Recent studies have indicated a growing popularity of navigation-assisted TKA techniques for achieving more precise joint inclination, particularly in terms of minor angular adjustments, compared to conventional mechanically aligned TKAs. Nevertheless, navigation-assisted techniques have also been linked to an increased likelihood of lateral inclination of the knee joint line when compared to kinematically aligned TKA procedures^[1,15,22].

It should be noted that this study is not without limitations. Firstly, the retrospective design may have introduced a degree of selection bias, as patient data were collected from historical records rather than being prospectively gathered. Furthermore, the relatively modest sample size of 60 knees may restrict the applicability of the findings to a broader population. A further limitation is the reliance on static radiographic parameters, which may not fully capture the dynamic aspects of knee function following TKA. Furthermore, the lack of long-term clinical outcomes precludes an evaluation of the true impact of joint line obliquity on implant survival and patient satisfaction. Furthermore, the study did not include a comparison between conventional and navigation-assisted TKA techniques, which could provide additional insights into achieving optimal joint line orientation in patients with severe varus deformities.

CONCLUSION

The findings of this study indicate that severe varus deformities are associated with a greater postoperative inclination of the lateral joint line than that observed in cases of mild to moderate deformities following mechanically-aligned TKA. Despite achieving the desired coronal alignment, these cases presented difficulties in restoring a parallel joint line orientation. This is the inaugural study to compare postoperative knee joint line orientations in patients with severe and mild to moderate varus deformities who underwent mechanically-aligned TKA. Although confounding factors such as preoperative knee joint line inclination and surgical technique (conventional, navigation-assisted, or kinematically aligned) may have influenced the results, the long-term effects of lateral joint line inclination on prosthesis survival remain unknown. Further long-term studies are required to address this issue. It is therefore recommended that particular attention be paid to anatomical parameters and soft tissue contractures during soft tissue release, osteotomy, and instrumentation to achieve optimal outcomes in patients with severe varus deformities.

DECLARATIONS

Ethics Committee Approval: The Ege University Faculty of Medicine Clinical Research Ethics Committee granted approval for this study (Date: 24.06.2014, number: 14-4.2/12).

Author Contributions: Idea/Concept – EKB, SA, HS; Design – EKB, MCS, SA; Control/Supervision – SA, HS; Data Collection and/or Processing – EKB, MCS, SA; Analysis and/or Interpretation – EKB, SA, HS; Literature review – EKB, MCS; Writing – EKB, MCS, SA; Critical Review – SA, HS.

Data Availability Statement: The data that support the findings of this study are available from the corresponding author upon reasonable request.

Conflict of Interest: The authors declared that they have no conflicts of interest with regard to this research.

Informed Consent: Informed consents were obtained from all participants prior to their inclusion in the study.

Use of AI for Writing Assistance: The authors declared that they had not used any type of generative artificial intelligence for the writing of this manuscript, nor for the creation of images, graphics, tables, or their corresponding captions.

Financial Disclosure: The authors declared that they have no relevant or material financial interests that relate to the research described in this paper.

Funding Disclosure: No funding was received for this study.

Peer-review: Externally peer-reviewed.

ABBREVIATIONS

TKA - Total Knee Arthroplasty

AP - Anteroposterior

RA - Rheumatoid Arthritis

OA - Osteoarthritis

SPSS - Statistical Package for the Social Sciences

FMA - Femoral Mechanical Axis

TMA - Tibial Mechanical Axis

SFA - Sagittal Femoral Angle

STA - Sagittal Tibial Angle

TFA - Tibiofemoral Angle

REFERENCES

- Hutt J, Massé V, Lavigne M, Vendittoli PA. Functional joint line obliquity after kinematic total knee arthroplasty. *Int Orthop (SICOT)* 2016;40:29–34. [\[CrossRef\]](#)
- Victor JM, Bassens D, Bellemans J, Gürsu S, Dhollander AA, Verdonk PC. Constitutional varus does not affect joint line orientation in the coronal plane. *Clin Orthop Relat Res* 2014;472:98–104. [\[CrossRef\]](#)
- Abdel MP, Oussedik S, Parratte S, Lustig S, Haddad FS. Coronal alignment in total knee replacement: historical review, contemporary analysis, and future direction. *J Bone Joint Surg* 2014;96:857–62. [\[CrossRef\]](#)
- Daniilidis K, Tibesku CO. Frontal plane alignment after total knee arthroplasty using patient-specific instruments. *Int Orthop (SICOT)* 2013;37:45–50. [\[CrossRef\]](#)
- Longstaff LM, Sloan K, Stamp N, Scaddan M, Beaver R. Good alignment after total knee arthroplasty leads to faster rehabilitation and better function. *The J Arthroplasty* 2009;24:570–8. [\[CrossRef\]](#)
- Babazadeh S, Dowsey MM, Swan JD, Stoney JD, Choong PF. Joint line position correlates with function after primary total knee replacement: a randomised controlled trial comparing conventional and computer-assisted surgery. *J Bone Joint Surg* 2011;93:1223–31. [\[CrossRef\]](#)
- Lee BS, Lee SJ, Kim JM, Lee DH, Cha EJ, Bin SI. No impact of severe varus deformity on clinical outcome after posterior stabilized total knee arthroplasty. *Knee Surg Sports Traumatol Arthrosc* 2011;19:960–6. [\[CrossRef\]](#)
- Howell SM, Papadopoulos S, Kuznik K, Ghaly LR, Hull ML. Does varus alignment adversely affect implant survival and function six years after kinematically aligned total knee arthroplasty?. *Int Orthop (SICOT)* 2015;39:2117–24. [\[CrossRef\]](#)
- Chin PL, Yang KY, Yeo SJ, Lo NN. Randomized control trial comparing radiographic total knee arthroplasty implant placement using computer navigation versus conventional technique. *J Arthroplasty* 2005;20:618–26. [\[CrossRef\]](#)
- Paley D, Herzenberg JE, Tetsworth K, McKie J, Bhave A. Deformity planning for frontal and sagittal plane corrective osteotomies. *Orthopedic Clinics of North America* 1994;25:425–66. [\[CrossRef\]](#)
- Bach CM, Steingruber IE, Peer S, Nogler M, Wimmer C, Ogon M. Radiographic assessment in total knee arthroplasty. *Clin Orthop Relat Res* 2001;385:144–50. [\[CrossRef\]](#)
- Hirschmann MT, Konala P, Amsler F, Iranpour F, Friederich NF, Cobb JP. The position and orientation of total knee replacement components: a comparison of conventional radiographs, transverse 2D-CT slices and 3D-CT reconstruction. *J Bone Joint Surg* 2011;93:629–33. [\[CrossRef\]](#)
- Gromov K, Korchi M, Thomsen MG, Husted H, Troelsen A. What is the optimal alignment of the tibial and femoral components in knee arthroplasty? An overview of the literature. *Acta orthopaedica* 2014;85:480–7. [\[CrossRef\]](#)
- Kim YH, Kim JS, Yoon SH. Alignment and orientation of the components in total knee replacement with and without navigation support: A prospective, randomised study. *J Bone Joint Surg* 2007;89:471–6. [\[CrossRef\]](#)
- Ji HM, Han J, San Jin D, Seo H, Won YY. Kinematically aligned TKA can align knee joint line to horizontal. *Knee Surg Sports Traumatol Arthrosc* 2016;24:2436–41. [\[CrossRef\]](#)
- Fang DM, Ritter MA, Davis KE. Coronal alignment in total knee arthroplasty: Just how important is it? *J Arthroplasty* 2009;24:39–43. [\[CrossRef\]](#)
- Gu Y, Roth JD, Howell SM, Hull ML. How frequently do four methods for mechanically aligning a total knee arthroplasty cause collateral ligament imbalance and change alignment from normal in white patients?: AAOS exhibit selection. *J Bone Joint Surg* 2014;96:e101. [\[CrossRef\]](#)
- Bellemans J, Colyn W, Vandenneucker H, Victor J. The Chitranjan Ranawat Award: is neutral mechanical alignment normal for all patients?: The concept of constitutional varus. *Clin Orthop Relat Res* 2012;470:45–53. [\[CrossRef\]](#)
- Gursu S, Sofu H, Verdonk P, Sahin V. Effects of total knee arthroplasty on ankle alignment in patients with varus gonarthrosis: Do we sacrifice ankle to the knee?. *Knee Surg Sports Traumatol Arthrosc* 2016;24:2470–5. [\[CrossRef\]](#)
- Vandekerckhove PJ, Matlovich N, Teeter MG, MacDonald SJ, Howard JL, Lanting BA. The relationship between constitutional alignment and varus osteoarthritis of the knee. *Knee Surg Sports Traumatol Arthrosc* 2017;25:2873–9. [\[CrossRef\]](#)
- Nishida K, Matsumoto T, Takayama K, Ishida K, Nakano N, Matsushita T, et al. Remaining mild varus limb alignment leads to better clinical outcome in total knee arthroplasty for varus osteoarthritis. *Knee Surg Sports Traumatol Arthrosc* 2017;25:3488–94. [\[CrossRef\]](#)
- Dossett HG, Swartz GJ, Estrada NA, LeFevre GW, Kwasman BG. Kinematically versus mechanically aligned total knee arthroplasty. *Orthopedics* 2012;35:e160–9. [\[CrossRef\]](#)