







Original Article

## Early Outcomes of Hip Arthroscopy in Tönnis Grade 2 Osteoarthritis Patients

 Yasin Erdogan,<sup>1</sup>  Enejd Veizi,<sup>2</sup>  Sahan Guven,<sup>2</sup>  Kemal Sibar,<sup>1</sup>  Emrah Imat,<sup>1</sup>  
 Aziz Ahmet Ulas,<sup>1</sup>  Ali Sahin<sup>1</sup>

<sup>1</sup>Department of Orthopedics and Traumatology, Ankara Etlik City Hospital, Ankara, Türkiye

<sup>2</sup>Department of Orthopedics and Traumatology, Ankara Bilkent City Hospital, Ankara, Türkiye

### ABSTRACT

**Objective:** Femoroacetabular impingement syndrome (FAIS) is a common cause of hip pain and significantly impairs quality of life. Morphological changes between the femur and acetabulum can lead to a range of pathologies, from focal cartilage defects to labral tears, which may ultimately progress to osteoarthritis. Evidence suggests that patients with osteoarthritis classified as Tönnis grades 0 and 1 typically benefit from hip arthroscopy. However, the available literature on the prognosis of patients with Tönnis grades 2 and higher remains limited. The short-term outcomes of hip arthroscopy were evaluated in patients with Tönnis stage 2 osteoarthritis whose symptoms persisted despite undergoing conservative treatment.

**Materials and Methods:** Patients who underwent hip arthroscopy with the diagnosis of femoroacetabular impingement syndrome at our center between 2020 and 2023 were included in the study. The inclusion criteria were patients diagnosed with femoroacetabular syndrome who had undergone hip arthroscopy and had been followed up for at least one year. Patients with Tönnis grade 0, 1, 3 and patients with bilateral surgery were excluded from the study. Tönnis stage 2 hips were included in the study. The clinical outcomes were assessed both pre-operatively and the last follow-up using the Modified Harris Hip Score (mHHS), the Non-arthritic Hip Score (NAHS), the Hip Disability and Osteoarthritis Score (HOOS), the Hip Outcome Score-Activities of Daily Living (HOS-ADL), the Hip Outcome Score-Sport Score (HOS-SS) and the Visual Analog Score (VAS).

**Results:** This study comprises a total of 26 patients, 15 males (57.7%) and 11 females (42.3%). The mean age of our patients was 38.3±9.8 years (range 19-56). The mean follow-up time of the patients was 24.5±3.8 months (range 15-37). Our patients exhibited significant improvement in preoperative scores, including mHHS, NAHS, HOS-Sports, HOS-ADL, and HOOS ( $p<0.001$ ). Additionally, the VAS scores decreased markedly from an average of 6.9±0.8 to 2.6±0.7 ( $p<0.001$ ).

**Conclusion:** This study revealed a significant improvement in early pain relief and functional outcomes in patients with Tönnis stage 2 osteoarthritis who underwent hip arthroscopy for the treatment of femoroacetabular impingement syndrome.

**Keywords:** Femoroacetabular impingement, hip arthroscopy, osteoarthritis, Tönnis stage



**Cite this article as:**

Erdogan Y, Veizi E, Guven S, Sibar K, Imat E, Ulas AA, et al. Early Outcomes of Hip Arthroscopy in Tönnis Grade 2 Osteoarthritis Patients. Sports Traumatol Arthrosc 2025;xx(xx):0-0.

**Address for correspondence:**

Yasin Erdogan.  
Department of Orthopedics and Traumatology, Ankara Etlik City Hospital, Ankara, Türkiye

**E-mail:**

yasin-erdgn@hotmail.com

**Submitted:** 21.10.2024

**Revised:** 22.12.2024

**Accepted:** 23.12.2024

**Available Online:** xx.xx.2025

Sports Traumatology & Arthroscopy –  
Available online at [www.stajournal.com](http://www.stajournal.com)



This work is licensed under a Creative Commons Attribution-NonCommercial 4.0 International License.

## INTRODUCTION

FAIS (femoroacetabular impingement syndrome) is a common cause of hip pain and leads to impaired quality of life [1,2]. As a result of abnormal contact between the femur and acetabulum, morphologic changes may occur in the femur, acetabulum or both. These changes vary from focal cartilage defects, cartilage detachment, chondro-labral separation to labral tears, eventually leading to osteoarthritis [3–5].

The Tönnis classification is generally used to classify osteoarthritis of the hip joint. It has been shown that patients with osteoarthritis of Tönnis grades 0 and 1 generally benefit from hip arthroscopy [6,7]. The Tönnis grade is reported to be one of the prognostic factors for the progression of osteoarthritis in patients who have undergone hip arthroscopy with a diagnosis of FAIS [8]. There are studies indicating that the prognosis is worse in patients with Tönnis grade 2 and higher and the rate of total hip arthroplasty (THA) is higher [9,10]. There is even concern that these patients may have poor clinical outcomes following hip arthroscopy, which may necessitate THA [11].

There are conflicting results in the literature regarding hip arthroscopy in patients with grade 2 Tönnis [12,13]. Nevertheless, several studies have reported favorable clinical outcomes of hip arthroscopy in patients with Tönnis grade 2 and higher [14,15]. Therefore, we wanted to share our short-term results after hip arthroscopy in patients with Tönnis grade 2 whose symptoms persisted despite conservative treatment.

## MATERIALS AND METHODS

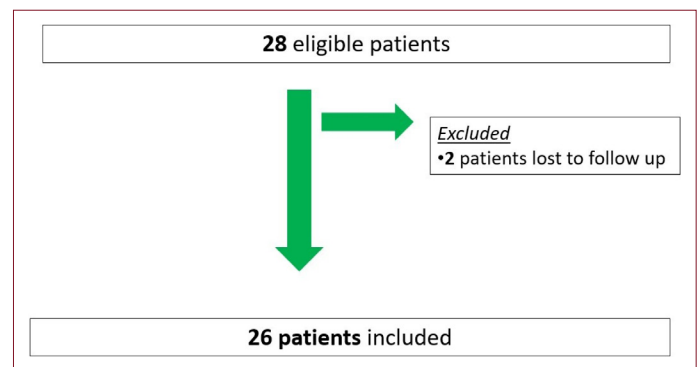
### Study Design

Patients who underwent hip arthroscopy with the diagnosis of femoroacetabular impingement syndrome at our center between 2020 and 2023 were included in the study. This retrospective study was approved by the local ethics committee (approval no: 2024-638). The inclusion criteria were patients diagnosed with femoroacetabular syndrome who had undergone hip arthroscopy and had been followed up for at least one year. Patients with Tönnis grade 0, 1, 3 and patients with bilateral surgery were excluded from the study. The radiographs of the patients were evaluated by two independent authors, and only those determined to be in Tönnis stage 2 by both authors were included in the study.

During the specified time period, 28 patients with grade 2 Tönnis underwent surgery. Due to incomplete follow-up of two patients, 26 patients were included in the study (Fig. 1).

### Surgical Technique & Rehabilitation

The patients were operated on in the supine position and on a traction table by a single experienced surgeon. A soft cylindrical perineal support with a diameter of 20 cm and a height of



**Figure 1.** Patients diagram.

35 cm was used to protect the groin area. After appropriate anesthesia, patient preparation was started. Traction was then applied. After providing adequate hip joint space for central compartment pathologies, standard anterolateral, mid-anterior and distal anterolateral accessory portals were created. Initially, existing forceps lesions were addressed using a superior labral approach. Following sufficient pincer excision, labrum repair was performed using suture anchors through the distal anterolateral accessory portal. Subsequently, traction was released, and the peripheral compartment was visualized. The existing cam lesion was excised under arthroscopic and fluoroscopic guidance. The capsule was then repaired, and the surgery was considered completed.

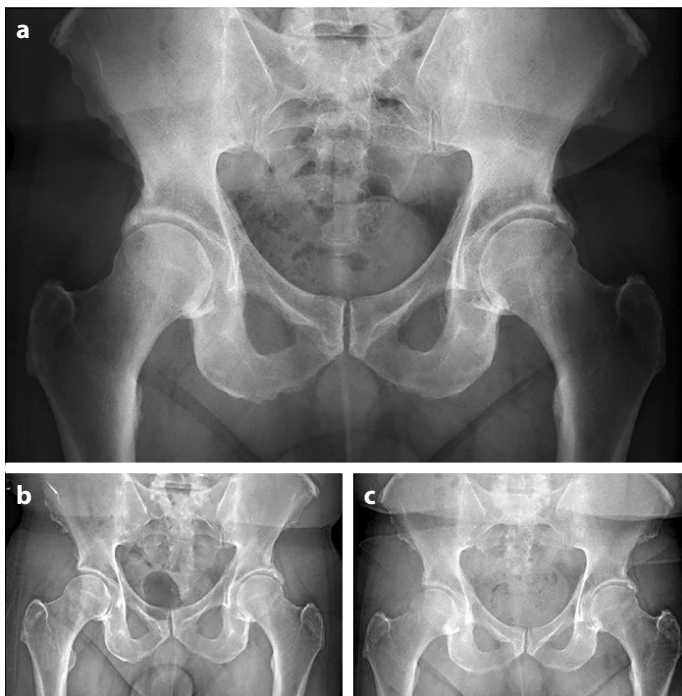
### Postoperative Rehabilitation and Follow-up

All patients were started on standard rehabilitation protocol with partial weight-bearing mobilization followed by isometric exercises. Rehabilitation protocol through phases 1–4 was then applied with minor individual changes according to patient condition.

The clinical outcomes were assessed both pre-operatively and at the last follow-up using the Modified Harris Hip Score (mHHS), the Non-arthritic Hip Score (NAHS), the Hip Disability and Osteoarthritis Score (HOOS), the Hip Outcome Score-Activities of Daily Living (HOS-ADL), the Hip Outcome Score-Sport Score (HOS-SS) and the Visual Analog Score (VAS). Radiographic evaluations were conducted during patient follow-ups (Fig. 2).

### Statistical Analysis

SPSS v25.0 (IBM, Chicago, USA) was used for statistical analysis. Continuous variables are shown as mean, standard deviation, median, and minimal to maximal data. Categorical data are shown as numbers and percentages. After distribution analyses, continuous variables were compared preoperatively and postoperatively using the Wilcoxon signed rank test. A value of  $p < 0.05$  was considered statistically significant.



**Figure 2.** (a) Preoperative radiograph showing a Tönnis grade 2 right hip, (b) Early postoperative radiograph of the patient, (c) Radiograph of the patient 26 months post-surgery.

## RESULTS

This study comprises a total of 26 patients, 15 males (57.7%) and 11 females (42.3%). The mean age of our patients was  $38.3 \pm 9.8$  years (range 19–56). The mean follow-up time of the patients was  $24.5 \pm 3.8$  months (range 15–37). 19 of the patients were operated on the right hip (73.1%) and 7 on the left hip (26.9%). The mean BMI of the patients was  $25.4 \pm 2.5$  (Table 1).

While the mean mHHS score of our patients before surgery was  $72.4 \pm 6.2$ , it increased to  $77.3 \pm 6.0$  at the last follow-up ( $p < 0.001$ ). While the average NASH score before surgery was  $54.6 \pm 13.5$ , it increased to  $72.9 \pm 10.4$  at the last follow-up ( $p < 0.001$ ).

While the mean HO-SPORTS score of our patients was  $63.7 \pm 7.3$  before surgery, it increased to  $73.7 \pm 5.8$  at the last follow-up ( $p < 0.001$ ). The mean HO-ADL score was  $63.4 \pm 4.1$  before surgery but increased to  $75.6 \pm 6.6$  at the last follow-up ( $p < 0.001$ ).

While the average HOOS score of our patients before surgery was  $62.7 \pm 5.8$ , it increased to  $73.0 \pm 6.4$  at the last follow-up ( $p < 0.001$ ). The VAS score decreased on average from  $6.9 \pm 0.8$  to  $2.6 \pm 0.7$  ( $p < 0.001$ ) (Table 2).

**Table 1.** Demographic and follow-up information of the study cohort

	n=26
Age	
Mean $\pm$ SD	38.3 $\pm$ 9.8
Median (min–max)	39 (19–56)
Side	
Right	19 (73.1%)
Left	7 (26.9%)
Gender	
Female	11 (42.3%)
Male	15 (57.7%)
BMI	
Mean $\pm$ SD	25.4 $\pm$ 2.5
Median (min–max)	26 (20–28)
Follow-up (months)	
Mean $\pm$ SD	24.5 $\pm$ 3.8
Median (min–max)	25 (15–37)

SD: Standard deviation; BMI: Body mass index.

**Table 2.** Comparison of preoperative and final follow-up scores of the study cohort

n=26	Preoperative values	Final follow-up values	p
	Mean $\pm$ SD Median (min–max)	Mean $\pm$ SD Median (min–max)	
mHHS	72.4 $\pm$ 6.2 76 (50–79)	77.3 $\pm$ 6.0 78 (58–88)	<0.001
NAHS	54.6 $\pm$ 13.5 60 (22–64)	72.9 $\pm$ 10.4 75 (33–82)	<0.001
HOS-SS	63.7 $\pm$ 7.3 64 (48–76)	73.7 $\pm$ 5.8 74 (58.3–80.6)	<0.001
HOS-ADL	63.4 $\pm$ 4.1 62 (51–69.4)	75.6 $\pm$ 6.6 73 (65–88)	<0.001
HOOS	62.7 $\pm$ 5.8 62 (51–75)	73.0 $\pm$ 6.4 71 (62–84.4)	<0.001
VAS	6.9 $\pm$ 0.8 7 (5–8)	2.6 $\pm$ 0.7 3 (1–4)	<0.001

mHHS: Modified Harris Hip Score; NAHS: Non-arthritis Hip Score; HOS-SS: Hip Outcome Score-Sport Score; HOS-ADL: Hip Outcome Score-Activities of Daily Living; HOOS - Hip Disability and Osteoarthritis Score; VAS: Visual Analog Score.

During the follow-up of our patients, no progression in the Tönnis stage was detected on X-ray imaging.

Four of our patients (15%) exhibited symptoms indicative of pudendal nerve damage; however, all symptoms resolved within a 5-month period. Heterotopic ossification was identified in one of our patients (3%).

## DISCUSSION

The most important result of our study is that the early functional results after hip arthroscopy in Tönnis grade 2 hips are significantly improved. The data demonstrated that, during the early period, patients experienced improvements in clinical functional scores and reductions in pain scores.

Studies have shown a correlation between femoroacetabular impingement and early osteoarthritis<sup>[16]</sup> and many patients with idiopathic osteoarthritis have been found to have FAI on previous radiographs. A study by Ecker et al.<sup>[17]</sup> emphasized that the risk of developing osteoarthritis in the future is high in hips with pathomorphological findings (cam, pincer). Viswanath and Khanduja<sup>[18]</sup> found that the cam/pincer lesion progresses to osteoarthritis as a result of damage to the chondrolabral junction. They even found a correlation between FAI and alpha angle above 60°<sup>[18]</sup>. Patients exhibiting morphological abnormalities on anteroposterior (AP) radiographs, particularly the presence of a posterior wall sign and a decreased medial proximal femoral angle, demonstrate a significantly higher likelihood of osteoarthritic progression<sup>[19]</sup>.

While the relationship between femoroacetabular impingement syndrome and osteoarthritis has become clearer in the literature, the benefit of hip arthroscopy in patients with hip osteoarthritis remains controversial<sup>[3,20]</sup>. In a systematic review conducted by Domb et al.<sup>[21]</sup> based on 13 articles, they found that patients with osteoarthritis at Tönnis stage 2 and above were significantly more likely to undergo total hip arthroplasty compared to patients without osteoarthritis. The cumulative risk of reoperation after hip arthroscopy for FAI, including revision surgery or conversion to THA, was 5.5% when including patients with stage 2 and above Tönnis hip osteoarthritis<sup>[22]</sup>. Moon et al.<sup>[23]</sup> showed in their study that patients who had undergone arthroscopy for FAI with labral tear had improved functional scores and no decrease in joint space after at least two years of follow-up. In our results, we observed a significant improvement in postoperative functional scores without the need for total hip arthroplasty during the follow-up period. We believe that these contradictions can be clarified in the literature with larger patient groups and longer follow-up periods.

In the study by Moon et al.<sup>[23]</sup>, mHHS increased from 74.8±13.2 preoperatively to 93±8.1 at the last follow-up, with a decrease in mHHS observed in five patients (5.6%). They found that WOMAC scores were 75±12.7 before surgery but increased to 89.4±8.4 at the last follow-up after surgery<sup>[23]</sup>. In a study conducted by Byrd et al.<sup>[14]</sup> on athlete patients, mHHS scores and return-to-sport rates were lower in Tönnis 2 patients than in Tönnis stage 0-1 patients, but they found no statistically significant difference. Lee et al.<sup>[24]</sup> reported that after hip arthroscopy in patients with early-stage osteoarthritis, mHHS scores decreased from 61.2 to 79.5, HOS-ADL scores decreased from 60.6 to 81.8, and VAS scores decreased from 6.3 to 3.2, and they found a significant improvement. Lee et al.<sup>[24]</sup> reported that after hip arthroscopy in patients with early-stage osteoarthritis, mHHS scores increased from 61.2 to 79.5, HOS-ADL scores increased from 60.6 to 81.8, and VAS scores decreased from 6.3 to 3.2, and they found a significant improvement. We also observed a significant increase in our patients' functional scores and a significant decrease in VAS scores.

Accurate patient selection and the management of patient expectations play a pivotal role in determining the success of arthroscopy in individuals with Tönnis grade 2 hip osteoarthritis. Evidence suggests that the success of femoroacetabular impingement (FAI) surgery is influenced more significantly by appropriate patient selection and expectation management than by technical aspects of the procedure<sup>[25]</sup>. Although our early patient outcomes appear favorable, the use of advanced preoperative imaging to precisely evaluate the extent of cartilage damage, combined with surgical decision-making tailored to patient expectations, may hold greater significance in achieving optimal results.

The main limitation of our study is that it is a retrospective study that includes only a small number of patients. Another important limitation is that it only reports the results of the Tönnis 2 patient group as a single group, without comparing it to any other group. However, we believe that the inclusion of functional scores reported by both patients and surgeons, which are currently used in the literature, will enrich the study. We believe that our study will pave the way for future investigations with larger and more diverse patient groups.

## CONCLUSION

This study showed significant improvement in early pain and function in patients who underwent hip arthroscopy for femoroacetabular impingement syndrome and Tönnis stage 2 osteoarthritis. This study is expected to illuminate future research that involves comparing larger and more diverse patient groups.

## DECLARATIONS

**Ethics Committee Approval:** The Ankara Etlik City Hospital Scientific Research Assessment and Ethics Committee granted approval for this study (Date: 17.07.2024, number: 2024-638).

**Author Contributions:** Idea/Concept – YE, KS; Design – YE, KS; Control/Supervision – AS, EV; Data Collection and/or Processing – EI, AAU; Analysis and/or Interpretation – EV; Literature review – YE, KS; Writing – YE, SG; Critical Review – EV.

**Data Availability Statement:** The data that support the findings of this study are available from the corresponding author upon reasonable request.

**Conflict of Interest:** The authors declared they have no conflict of interest with regard to the results of this study.

**Informed Consent:** Informed consents were obtained from all participants prior to their inclusion in the study.

**Use of AI for Writing Assistance:** Artificial intelligence-supported technologies were not used in the study.

**Financial Disclosure:** The authors declared that they have no relevant or material financial interests that relate to the research described in this paper.

**Funding Disclosure:** The authors declared that they received no funding during or after this study.

**Peer-review:** Externally peer-reviewed.

## ABBREVIATIONS

FAI - Femoroacetabular impingement

FAIS - Femoroacetabular impingement syndrome

mHHS - Modified Harris Hip Score

NAHS - Non-arthritic Hip Score

HOOS - Hip Disability and Osteoarthritis Score

HOS-ADL - Hip Outcome Score-Activities of Daily Living

HOS-SS - Hip Outcome Score-Sport Score

VAS - Visual Analog Score

THA - Total hip arthroplasty

## REFERENCES

- Langhout R, Weir A, Litjes W, Gozeling M, Stubbe JH, Kerkhoffs G, et al. Hip and groin injury is the most common non-time-loss injury in female amateur football. *Knee Surg Sports Traumatol Arthrosc* 2019;27:3133–41. [\[CrossRef\]](#)
- Papalia R, Del Buono A, Franceschi F, Marinozzi A, Maffulli N, Denaro V. Femoroacetabular impingement syndrome management: Arthroscopy or open surgery? *Int Orthop* 2012;36:903–14. [\[CrossRef\]](#)
- Ganz R, Leunig M, Leunig-Ganz K, Harris WH. The etiology of osteoarthritis of the hip: An integrated mechanical concept. *Clin Orthop Relat Res* 2008;466:264–72. [\[CrossRef\]](#)
- Agricola R, Heijboer MP, Bierma-Zeinstra SM, Verhaar JA, Weinans H, Waarsing JH. Cam impingement causes osteoarthritis of the hip: A nationwide prospective cohort study (CHECK). *Ann Rheum Dis* 2013;72:918–23. [\[CrossRef\]](#)
- Migliorini F, Maffulli N, Baroncini A, Eschweiler J, Tingart M, Betsch M. Revision surgery and progression to total hip arthroplasty after surgical correction of femoroacetabular impingement: A systematic review. *Am J Sports Med* 2022;50:1146–56. [\[CrossRef\]](#)
- Palmer AJR, Ayyar Gupta V, Fernquest S, Rombach I, Dutton SJ, Mansour R, et al; FAIT Study Group. Arthroscopic hip surgery compared with physiotherapy and activity modification for the treatment of symptomatic femoroacetabular impingement: multicentre randomised controlled trial. *BMJ* 2019;364:l185. Erratum in: *BMJ* 2021;372:m3715. [\[CrossRef\]](#)
- Griffin DR, Dickenson EJ, Wall PDH, Achana F, Donovan JL, Griffin J, et al; FASHIoN Study Group. Hip arthroscopy versus best conservative care for the treatment of femoroacetabular impingement syndrome (UK FASHIoN): A multicentre randomised controlled trial. *Lancet* 2018;391:2225–35. [\[CrossRef\]](#)
- Ke L, Kou WG, Ma C, Zhang YZ, Liu DS. Risk factors for hip osteoarthritis after arthroscopy in patients with femoroacetabular impingement.v [Article in Chinese]. *Zhongguo Gu Shang* 2024;37:179–83.
- Comba F, Yacuzzi C, Ali PJ, Zanotti G, Buttaro M, Piccaluga F. Joint preservation after hip arthroscopy in patients with FAI. Prospective analysis with a minimum follow-up of seven years. *Muscles Ligaments Tendons J* 2016;6:317–23. [\[CrossRef\]](#)
- Chandrasekaran S, Darwish N, Gui C, Lodhia P, Suarez-Ahedo C, Domb BG. Outcomes of hip arthroscopy in patients with Tönnis Grade-2 osteoarthritis at a mean 2-year follow-up: Evaluation using a matched-pair analysis with Tönnis grade-0 and grade-1 cohorts. *J Bone Joint Surg Am* 2016;98:973–82. [\[CrossRef\]](#)
- Yacovelli S, Sutton R, Vahedi H, Sherman M, Parvizi J. High risk of conversion to THA after femoroacetabular osteoplasty for femoroacetabular impingement in patients older than 40 years. *Clin Orthop Relat Res* 2021;479:1112–8. [\[CrossRef\]](#)
- Andronic O, Claydon L, Cubberley R, Sunil-Kumar KH, Khanduja V. Outcomes of hip arthroscopy in patients with femoroacetabular impingement and concomitant Tönnis grade II osteoarthritis or greater: Protocol for a systematic review. *Int J Surg Protoc* 2021;25:1–6. [\[CrossRef\]](#)
- Andronic O, Claydon-Mueller LS, Cubberley R, Karczewski D, Sunil-Kumar KH, Khanduja V. Inconclusive and

- contradictory evidence for outcomes after hip arthroscopy in patients with femoroacetabular impingement and osteoarthritis of Tönnis grade 2 or greater: A systematic review. *Arthroscopy* 2022;38:2307–18. [\[CrossRef\]](#)
14. Byrd JWT, Jones KS, Bardowski EA. Influence of Tönnis grade on outcomes of arthroscopy for FAI in athletes: A comparative analysis. *J Hip Preserv Surg* 2018;5:162–5. [\[CrossRef\]](#)
  15. Byrd JW, Jones KS. Arthroscopic management of femoroacetabular impingement: minimum 2-year follow-up. *Arthroscopy* 2011;27:1379–88. [\[CrossRef\]](#)
  16. Kowalczyk M, Yeung M, Simunovic N, Ayeni OR. Does femoroacetabular impingement contribute to the development of hip osteoarthritis? A systematic review. *Sports Med Arthrosc Rev* 2015;23:174–9. [\[CrossRef\]](#)
  17. Ecker TM, Tannast M, Puls M, Siebenrock KA, Murphy SB. Pathomorphologic alterations predict presence or absence of hip osteoarthrosis. *Clin Orthop Relat Res* 2007;465:46–52. [\[CrossRef\]](#)
  18. Viswanath A, Khanduja V. Can hip arthroscopy in the presence of arthritis delay the need for hip arthroplasty? *J Hip Preserv Surg* 2017;4:3–8. [\[CrossRef\]](#)
  19. Bardakos NV, Villar RN. Predictors of progression of osteoarthritis in femoroacetabular impingement: A radiological study with a minimum of ten years follow-up. *J Bone Joint Surg Br* 2009;91:162–9. [\[CrossRef\]](#)
  20. Greaves LL, Gilbert MK, Yung AC, Kozlowski P, Wilson DR. Effect of acetabular labral tears, repair and resection on hip cartilage strain: A 7T MR study. *J Biomech* 2010;43:858–63. [\[CrossRef\]](#)
  21. Domb BG, Gui C, Lodhia P. How much arthritis is too much for hip arthroscopy: A systematic review. *Arthroscopy* 2015;31:520–9. [\[CrossRef\]](#)
  22. Minkara AA, Westermann RW, Rosneck J, Lynch TS. Systematic review and meta-analysis of outcomes after hip arthroscopy in femoroacetabular impingement. *Am J Sports Med* 2019;47:488–500. [\[CrossRef\]](#)
  23. Moon JK, Yoon JY, Kim CH, Lee S, Kekatpure AL, Yoon PW. Hip arthroscopy for femoroacetabular impingement and concomitant labral tears: A minimum 2-year follow-up study. *Arthroscopy* 2020;36:2186–94. [\[CrossRef\]](#)
  24. Lee JK, Hwang DS, Kang C, Hwang JM, Lee GS, Zeng L, et al. Midterm-clinical outcomes after hip arthroscopy in middle-aged patients with early osteoarthritis. *Hip Pelvis* 2020;32:17–25. [\[CrossRef\]](#)
  25. Horner NS, Ekhtiari S, Simunovic N, Safran MR, Philippon MJ, Ayeni OR. Hip arthroscopy in patients age 40 or older: A systematic review. *Arthroscopy* 2017;33:464–75. [\[CrossRef\]](#)